



Chapter 16

FACIAL LACERATIONS

KEY FIGURES:

Tissue flap

Suture bites: face vs. rest of body

Lip anatomy

Soft tissue loss

The face has several unique properties that dictate the choice of treatment after injury. This chapter describes basic principles for the treatment of facial wounds as well as treatment recommendations for injuries involving specific areas of the face.

Unique Properties of Facial Lacerations

Cosmetic Concerns

Although most people do not want an unsightly scar anywhere on the body, they are especially concerned about scars on their face. Thus, primary closure, which usually results in the least noticeable scar, is the preferred treatment for most facial lacerations. Fortunately, because of the laxity of facial skin, most wounds can be repaired primarily unless they have significant tissue loss or tissue swelling.

Better Blood Supply and Circulation

The skin of the face has a more abundant blood supply compared with other areas of the body. As a result, lacerations on the face can be closed more than 6 hours after injury (the usual time limit for closure of an acute laceration) without a high risk for subsequent wound infection. As long as the wound can be cleansed thoroughly, facial lacerations often can be closed even the day after injury.

Because of the better blood supply, a wound that is closed primarily can tolerate more tension on the suture line than is usually allowed. But do *not* take this principle to an extreme. If there is significant blanching of the skin with the closure, you may not want to close the wound completely. In this instance, merely place a few sutures to close the wound partially and thus decrease the size of the scar.

Initial Care

The initial care of a facial wound is the same as the care applied to any wound. As explained in chapter 6, "Evaluation of an Acute Wound," the wound needs to be cleansed fully and examined thoroughly. All foreign material, blood, and necrotic tissue should be removed. Debridement of skin edges should be kept to a minimum, unless the tissue is obviously dead. Because of the excellent blood supply of the face, tissue that seems ischemic often survives.

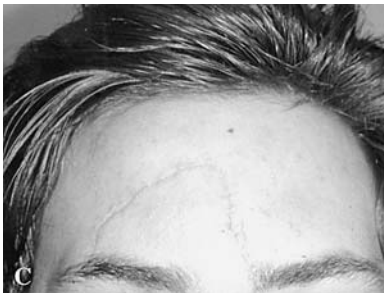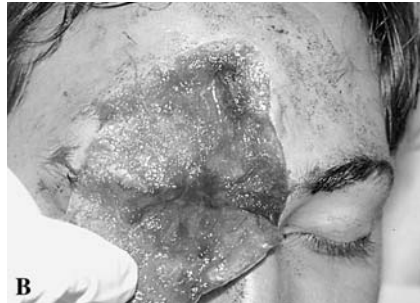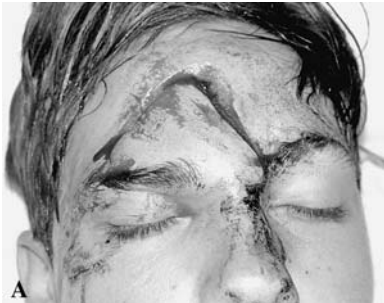Paint the injured area with an antibacterial solution before closing the wound. Be careful: some solutions can cause injury to the eyes. Ten percent povidone iodine solution is commonly available and will not injure the eyes. It also can be used safely on oral mucosa.

Anesthesia

A more thorough description of the administration of local anesthetics is found in chapter 3, "Local Anesthesia." Below is a brief overview.

Agents

Lidocaine with epinephrine is the best choice of anesthetic with one exception: when a flap is raised by the injury. In this case, it is best to use plain lidocaine in order not to diminish circulation to the flap.



Tissue flap in patient who fell through a glass window. *A*, Irregular forehead laceration. *B*, The skin is separated from the deep tissue layers of the forehead, creating a skin flap with marginal blood supply. Do *not* add epinephrine to the anesthetic solution; it will decrease circulation to the flap and may cause the tissue to die. *C*, One month after repair. All of the skin has survived and is healing without complication.

Bupivacaine is also acceptable. Add bicarbonate to decrease the pain of injection.

Administration of Local Anesthetic

For **smaller lacerations** (a few centimeters or less), it is often easiest to inject the anesthetic along the wound edges.

For **larger lacerations** or lacerations around the edge of the lip (where local injection can distort landmarks), a nerve block is usually more effective.

Nerve Blocks on the Face

Mental nerve block: lower lip, skin below the lip.

Infraorbital nerve block: upper lip, lateral nose, lower eyelid, medial cheek.

Supraorbital/supratrochlear nerve block: forehead.

Suture Choice

Nylon is the suture material of choice to close a skin wound on the face.

Chromic or other absorbable material should be used for mucosal lacerations.

If you believe that the patient will not return for suture removal or if the patient is a child in whom suture removal is likely to be quite difficult, chromic (absorbable material of choice) sutures can be used on facial skin.

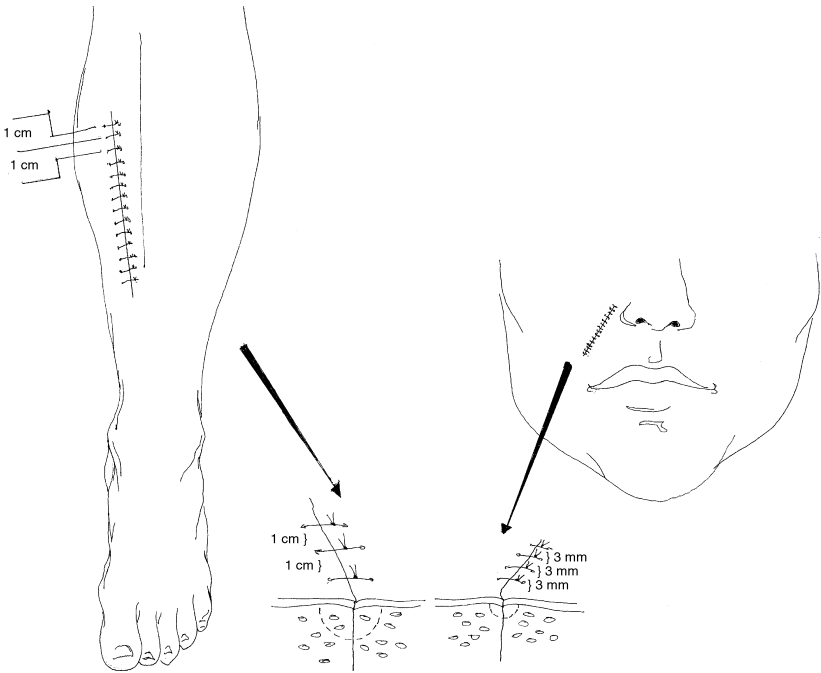
The appropriate size of the suture is discussed in the sections describing specific injuries.

Suture Placement

Sutures on the face should be placed a little closer together than usually recommended because of cosmetic concerns. The sutures should be placed 1–2 mm from the skin edge and 3 mm apart to achieve better tissue approximation. Exceptions are noted in specific descriptions below.

If you have access to magnifying glasses, use them. They help to achieve better tissue alignment because the magnification allows more accurate placement of the sutures.

Most facial lacerations can be closed in one layer. Exceptions will be noted.



Suture bites: face vs. rest of the body. Sutures placed on the face should be approximately 1–2 mm from the skin edge and approximately 3 mm apart. This technique requires the use of small suture material.

Continuous vs. Interrupted Closure

A laceration in which skin edges can be aligned easily and without tension can be closed with either technique.

Irregular lacerations or lacerations in which you are concerned about the potential for infection should be closed in an interrupted fashion for the following reasons:

1. If, a few days after wound closure, a localized area starts to look infected, you can treat the infection without having to open the entire wound. Just remove a few sutures in the area that looks red, open the skin, and wash the wound with saline. This will allow the wound to drain and may allow the infection to resolve while keeping the resultant scar relatively small. The patient also should be given antibiotics.
2. If the wound had been closed by placing the sutures in a continuous fashion, partial removal of the suture is not possible. If the wound looks infected, the entire suture will need to be removed and thus the entire wound will reopen. This results in a much larger scar.

Suture Removal

Sutures should be removed after 5–7 days to minimize scarring.

Postrepair Instructions

1. After the wound edges are sutured together, apply a small amount of antibiotic ointment over the suture line. Cover with a dry gauze. The dressing can be removed on the following day.
2. The area should be cleansed once or twice daily with gentle soap and water. The patient can shower and wash the face as usual on the day after the repair.
3. After cleansing, a small amount of antibiotic ointment or a petrolatum type ointment should be applied over the suture line. If the patient desires, dry gauze can be used to cover the area, although it usually is not necessary unless the patient is in a dirty environment.
4. Facial injuries cause the tissues to swell. Be sure to warn your patient that the face will be swollen for several days after injury. To minimize swelling, instruct the patient to keep the head elevated at all times. When reclining, an extra pillow (or folded sheet) should be placed under the head.
5. The patient also should avoid bending and heavy lifting for several days after the injury because such activities promote facial swelling.

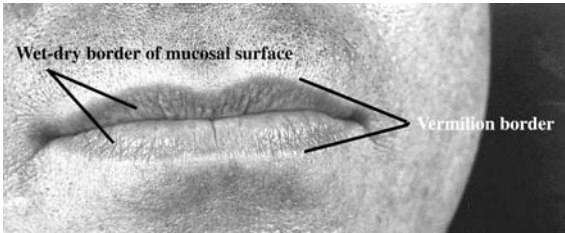
Specific Wounds

Lip Lacerations

The **vermilion border** is the edge of the lip where the red part of the lip ends and the white skin begins. It is vital to realign the vermilion border meticulously to prevent a noticeable notched irregularity.

The red part of the lip is the **mucosal surface**, which can be divided into two parts. The part of the lip that you see when the lips are barely separated is called the **dry mucosa** because it feels dry to touch. The mucosal surface that lies against the teeth and appears and feels wet is called the **wet mucosa**. These distinctions are important. Try to align the border between these two surfaces to prevent a relatively subtle, but noticeable irregularity.

To make it easier to see the various “borders,” it is best to use a nerve block for repair of lip lacerations. If you are unable to do this, inject the local anesthetic a few millimeters away from the wound edge and wait longer than usual (5–10 min) for the swelling from the injection to resolve.



Important anatomic landmarks of the lip.

Mucosal Lacerations

- The key to successful repair is to realign the wet-dry mucosal border, as explained above.
- Place the first stitch at the border between the wet and dry surfaces.
- Use absorbable sutures, 4-0, and try to sew the wet mucosa to wet mucosa and the dry mucosa to dry mucosa.
- It is important to evert the edges; use mattress sutures if necessary.
- Tie at least 4 or 5 knots in the sutures to prevent the sutures from coming undone because the patient unconsciously pulls at them with the tongue.

Partial-thickness Lacerations that Cross the Vermilion Border

- The key to successful repair is to approximate the vermilion border as well as possible.
- Align the red/white margin first. Place the initial suture just above the vermilion border in the white upper lip skin. Use a 5-0 or 6-0 suture.
- If the stitch does not seem to be well-placed, remove it and try again.
- Place the remaining sutures in the lip skin (5-0 or 6-0) and lip mucosa (4-0 or 5-0). Be sure to evert the skin edges.

Full-thickness Lacerations

In full-thickness lip lacerations, the outer skin, lip muscle, and mucosa have all been cut. Full-thickness lip lacerations often look scary. Because muscle retracts when cut, the lip wound looks larger and more complex than it is. Most of these wounds can be repaired easily. Primary repair is possible even if approximately one-fourth of the upper or lower lip is lost. Repair includes the following steps:

1. It often helps to place a gauze pad between the gums and lip to collect blood or other fluids.
2. **If bleeding is significant:** injection of lidocaine with epinephrine usually controls bleeding from the lip surface. However, if the bleeding is coming from a cut artery, you may need to place a stitch in the artery. Use a 4-0 absorbable suture, and place a simple or figure-of-eight suture at the site of bleeding. When you tie the suture, the bleeding should stop.
3. **Repair the mucosa:** repair the inner aspect of the lip first, as described above under "Mucosal Lacerations." Use an absorbable 4-0 suture, and try to evert the edges.
4. **Irrigate the wound** with saline again after the mucosa is closed to cleanse the wound.
5. **Repair the muscle:** use an absorbable suture, 3-0 or 4-0, and place one or two figure-of-eight sutures in the muscle. If you look carefully at the wound edges, the muscle and mucosa have a different appearance and texture. Take care not to catch any mucosa in the stitches; if you do, you will cause a pucker in the mucosa.
6. **Repair the skin:** as well as possible, align the vermilion border as described above. Remember to tie 4 or 5 knots in the lip sutures, which often come undone because the patient unconsciously pulls at them.

Intraoral Mucosal Lacerations

Lacerations may occur inside the mouth. When they occur along the inside of the cheek, you must be careful to *avoid injury to the opening of the parotid duct* (through which the secretions of the parotid gland enter the mouth) during the repair. The opening of the duct into the mouth is a small, raised mound of mucosa inside the cheek across from the upper second molar. You do not want to accidentally place a suture across this structure.

- Use absorbable sutures, 4-0 or 3-0.
- Do *not* take big bites of tissue. Go about 2–3 mm from the edge of the wound and include only the mucosa in your suture. Do *not* include muscle or other underlying tissues.
- Be sure to evert the edges.
- You do *not* need to place the sutures close together. Usually only a few are needed (0.5–0.7 cm apart) to approximate the edges.

Tongue Lacerations

- Use lidocaine with epinephrine to control bleeding.
- Because the tongue is a muscle, the edges retract when it is cut, making the wound appear more complicated than it is.
- If you can, place an absorbable 3-0 suture in a figure-of-eight fashion in the inner muscle. If you cannot place this stitch, take deeper than usual bites when repairing the tongue edges. Use 3-0 or 4-0 absorbable sutures.
- Take larger bites, 4–5 mm from the edge, and include the underlying muscle to control bleeding.

Full-thickness Cheek Lacerations

A full-thickness cheek laceration implies that the cheek skin, underlying subcutaneous tissue/muscle, and intraoral mucosa have been injured. Such wounds must be repaired in layers.

Intraoral Mucosa

- The intraoral mucosa should be repaired first, using the previously described technique.
- When the mucosa is closed, it separates the oral cavity from the outer wound.
- To decrease contamination by oral flora, the wound again should be irrigated with saline once the opening into the mouth is repaired. Paint the area with an antibacterial solution.

Skin and Subcutaneous Tissue/Muscle

- Skin and subcutaneous layers often can be brought together simply by repairing the skin. Use 5-0 nylon sutures for skin closure.
- If bringing the skin edges together does not allow the subcutaneous tissue to fill in the wound, place one or two (depending on the size of the wound) 4-0 absorbable simple sutures to approximate the muscle or subcutaneous tissue.
- Do not place too many sutures, or you risk injury to the facial nerve or other deep structures.

Full-thickness Nasal Lacerations

A full-thickness nasal laceration includes injury to the external skin, cartilage, and nasal mucosa.

Skin

- It is best to use plain lidocaine on the skin of the nose.
- Small, 5-0 nonabsorbable sutures are preferable, placed a few millimeters from the edges.
- Try to align the alar rim (the edge of the nostril) as well as possible to prevent notching. This goal is often problematic if the laceration completely tears the alar rim.

Cartilage

The cartilage usually is brought to an acceptable position when the skin laceration is repaired. Placement of sutures directly in the cartilage is not usually recommended.

Nasal Mucosa

- Primary repair of nasal mucosa can be challenging because you are working in a small, dark space; nevertheless, it is important to try. If the nasal mucosa is not properly repaired, the result may be a tight scar inside the nose, which can obstruct nasal breathing.
- To control bleeding from the mucosa, use lidocaine with epinephrine for local anesthesia.
- Use small, absorbable 5-0 chromic sutures. You do not need many.
- Once the repair is complete, loosely pack the affected nostril with gauze coated with antibiotic ointment. Leave the gauze in place for a few days to encourage healing with less scar contracture. The patient should take an oral antibiotic (e.g., cephalosporin) as long as the packing is in place.

Eyelid Lacerations

Caution is mandatory when an antibiotic ointment is used around the eye. Use only an ophthalmic ointment because regular antibiotic ointment can cause conjunctivitis.

Eyelid Skin Alone

The eyelid skin should be repaired loosely with simple sutures. Use 5-0 or 6-0 sutures, absorbable or nonabsorbable. If you use nonabsorbable sutures, remove them in 3-4 days.

Full-thickness Injuries

In full-thickness eyelid lacerations, skin, muscle, usually tarsal plate, and underlying conjunctiva are cut. The conjunctiva does not usually need to be closed as a separate layer. It will heal if the overlying tissues are well aligned. Use the following procedure:

1. Start by placing a small suture (5-0 or 6-0 is best) to reapproximate the gray line (where the eyelid meets the conjunctiva, i.e., the lash margin).
2. Keep the knot away from the eyeball because irritation or potentially an ulceration may result if the knot rubs on the conjunctiva or cornea.
3. Use absorbable 5-0 sutures to reapproximate the tarsal plate and orbicularis muscle in one layer.
4. Close the skin as described above.

Tearduct Injuries

An injury to the tearduct should be considered in full-thickness eyelid lacerations within 6–8 mm of the medial canthus (where the upper and lower eyelids meet near the side of the nose). If tearduct probes and stents are available, the duct should be probed and possibly stented. Probing a tearduct is quite difficult and requires special technical expertise and training. Do *not* attempt to probe a tearduct if you have not done it before.

Injuries with Tissue Loss

Primary closure of the eyelid can be done even with up to 25% full-thickness tissue loss. More than 25% full-thickness tissue loss requires more complicated flaps.

Partial-thickness loss (i.e., skin loss with underlying muscle and conjunctiva intact or repairable) can be covered with a full-thickness skin graft. In the medial canthal area, a defect smaller than 1 cm often can be allowed to heal by secondary intention.

The full-thickness skin graft can be taken from the other upper eyelid, if the patient has redundant upper eyelid skin. See more details in chapter 12, “Skin Grafts.”

Eyebrow Lacerations

A laceration that involves the eyebrow should be reapproximated to recreate the natural curve of the eyebrow as well as possible. Leave the suture ends long so that you can easily distinguish them from the eyebrow hairs.

One caveat: do *not* shave the eyebrow. The hair may not grow back normally.

Full-thickness Forehead Lacerations

A full-thickness forehead laceration involves skin and underlying muscle. The bone of the skull is usually exposed. Such wounds must be repaired in layers to prevent a significant contour irregularity.

Frontal Sinus Fractures

The paired frontal sinuses are found at the center of the forehead, just above the bridge of the nose. If you can see a fracture of the anterior wall of the frontal sinus, the patient must have a computed tomography (CT) scan of the head to evaluate injury to the posterior wall of the frontal sinus and brain. If such injuries are present, a neurosurgeon is needed.

If the anterior wall is depressed, try to bring the bones outward to the appropriate position before closing the wound. Optimally, the bones should be immobilized with tiny plates and screws. This procedure requires a specialist and may be done at a later date. The following sections describe only soft tissue repair.

Frontalis Muscle with Overlying Fascia

The muscle and fascia should be brought together with a few simple or figure-of-eight, 3-0 or 4-0 absorbable sutures.

Skin

Repair the skin with 5-0 simple sutures.

Full-thickness Scalp Lacerations

Full-thickness scalp lacerations can be quite serious. Because of the abundant blood supply to the scalp, patients can lose a significant, even life-threatening amount of blood. It is acceptable to shave the surrounding hair to allow thorough examination of the wound. The hair will grow back.

Layers of the Scalp

Classically, the scalp is described as having five layers. From outside to inside, they can be remembered with the mnemonic **SCALP**:

S = Skin

C = subCutaneous tissue

A = galea Aponeurosis (essentially the muscle layer)

L = Loose connective tissue

P = Periosteum (also called pericranium), which overlies the bone

For practical purposes, in patients with a full-thickness scalp laceration (i.e., all layers of the scalp are divided and the skull is exposed), you must close the galea and the skin.

Closing the galea layer often controls the brisk bleeding associated with scalp wounds. If a wound infection develops at the site of injury, closure of the galea layer also prevents the infection from spreading under the entire scalp. Once infection reaches the loose connective tissue plain (deep to the galea), it can spread widely. Closure of the galea prevents this potentially serious complication.

How to Control Bleeding as Well as Close the Wound

1. Lidocaine with epinephrine should be used whenever possible for local anesthesia.
2. Suture together the galea layer with 3-0 or 4-0 Vicryl or chromic sutures. They can be placed in a simple fashion or in a figure-of-eight fashion.
3. Close the skin with a continuous locking suture of 3-0 nylon or Vicryl. The skin stapler (if available) is a useful, fast technique for scalp closure.

Full-thickness External Ear Lacerations

Posterior Side of the Ear

Use 4-0 or 5-0 absorbable sutures. It is best to place them in an interrupted fashion.

Cartilage

1. If the cartilage is highly irregular, gently trim the edges to smooth it out.
2. Be sure to cleanse the wound meticulously when the cartilage is involved. All foreign material must be removed. If dirt is embedded in the cartilage, the cartilage should be trimmed to remove the dirt particles.
3. No sutures need to be placed in the cartilage. When placing sutures in the skin, try to include the perichondrium (the thin layer of loose tissue overlying the cartilage). In this way, the cartilage edges are brought together as the skin is repaired.

Anterior Side of the Ear

Use 4-0 or 5-0 nonabsorbable sutures placed in an interrupted fashion. Absorbable sutures also may be used.

How to Prevent Hematoma Formation

A particularly concerning complication associated with ear lacerations is the development of a hematoma. If blood collects and pressure builds up between the skin and cartilage, the result may be a noticeable ear deformity, so-called cauliflower ear. A properly placed dressing helps to prevent this complication. You should see the patient on the next day, if possible, to check for a hematoma.

Dressing

1. Add antibiotic ointment to a piece of gauze, and place it over the repair site. Gently press it onto the external ear to conform to the shape of the ear.
2. Open and fluff up several dry gauze pads, and place them around the ear, filling the contours of the ear with gauze. Make sure to place some gauze behind the ear as well.
3. Gently wrap the head and ear with gauze wrap and a light Ace wrap. Do not make the wrap tight. Try to leave it in place for 24–48 hours.

What to Do if a Hematoma Develops

If the patient returns (usually within the first few days after injury) with pain and swelling of the ear, a hematoma may be present. The ear looks purplish, and the swelling demonstrates some “give” when you push on it. Blood may ooze out of the suture line, and the ear may be slightly warm. If a hematoma develops, follow the procedure outlined below:

1. The sutures should be removed and the blood drained.
2. The wound should be thoroughly washed and then closed loosely.
3. Use fewer sutures than you used the first time.
4. Apply a dressing similar to the original one.
5. An oral antibiotic, taken for 24 hours, may be a useful precaution.

Summary of the Optimal Suture Material for Specific Facial Wounds

Site of Injury	Optimal Suture Size*	Optimal Suture Material (Good Alternate Choice)
Cheek, forehead, or nose skin	5-0,6-0	Nylon, Prolene [†] (chromic for children or patients who cannot return for suture removal)
Ear skin	4-0	Nylon (chromic)
External tongue mucosa	4-0	Chromic (Vicryl/Dexon) [‡]
Eyelid skin	5-0, 6-0	Nylon (chromic)
Frontalis (forehead) muscle	3-0, 4-0	Polydioxanone (Vicryl/Dexon, chromic)
Galea (scalp)	3-0, 4-0	Polydioxanone (Vicryl/Dexon, chromic)
Lip or intraoral mucosa	4-0	Chromic (Vicryl/Dexon)
Lip muscle	4-0	Vicryl/Dexon (chromic, polydioxanone)
Lip skin	5-0, 6-0	Nylon (chromic)
Nasal mucosa	5-0	Chromic
Scalp skin	3-0, 4-0	Nylon (staples, chromic)
Subcutaneous tissue	4-0, 5-0	Vicryl/Dexon (chromic)
Tongue muscle	3-0	Vicryl/Dexon (chromic, polydioxanone)

* If you have a choice, these sizes are recommended.

[†] Prolene can be substituted whenever nylon is recommended.

[‡] Vicryl is a polyglactac acid; Dexon is a polyglycolic acid. They are essentially interchangeable.

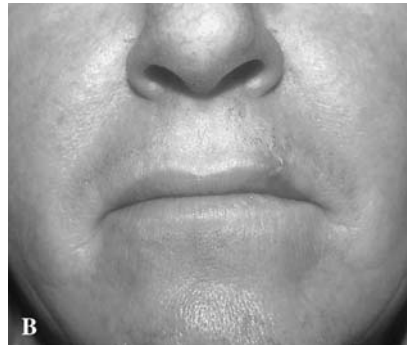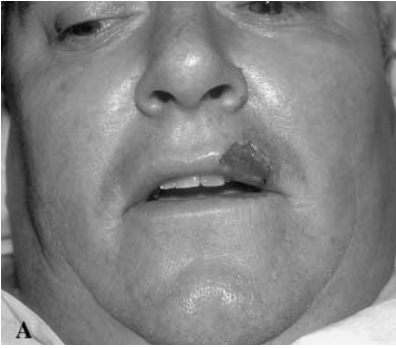Facial Lacerations with Soft Tissue Loss

If the laceration is relatively small (< 1 cm), it often may be left alone and allowed to heal secondarily, especially if it is located in the medial canthal area, the skin around the upper and lower lip, or the lateral aspects of the bridge of the nose.

Larger wounds (even a few cm in size) involving the lateral cheek area (in front of the ear but not near the lower eyelid) and the forehead also may be allowed to heal secondarily with good results.

Be careful around the cheek near the lower eyelid. Allowing a skin defect to heal secondarily in this area may result in a pulling down of the lower eyelid (called an ectropion). This serious complication may result in injury to the cornea. To prevent an ectropion, a full-thickness skin graft or local flap should be used for soft tissue loss near the lower eyelid.

A local flap or full-thickness skin graft also may be required for other larger face wounds or wounds involving the nasal tip. See chapter 12, "Skin Grafts," and chapter 13, "Local Flaps," for details. Significant soft tissue loss of the lip or eyelid (> 25%) requires the help of a specialist.



Soft tissue loss. *A*, Dog bite to the upper lip resulting in soft tissue loss. The wound was allowed to heal secondarily. *B*, One year after injury, the lip has a nice contour with minimal scarring.

Bibliography

Goldwyn RM, Rueckert F: The value of healing by secondary intention for sizable defects of the face. *Arch Surg* 112: 285, 1977.