



Chapter 13

LOCAL FLAPS

KEY FIGURES:

Axial flap noting pedicle
Random flap noting
pedicle and 3:1 ratio

Rhomboid flap
Rotation flap
V-Y advancement flap

Definitions

A **flap** is a piece of tissue with a blood supply that can be used to cover an open wound. A flap can be created from skin with its underlying subcutaneous tissue, fascia, or muscle, either individually or in some combination. Depending on the reconstructive requirements, even bone can be included in a flap.

A **local flap** implies that the tissue is adjacent to the open wound in need of coverage, whereas in a **distant flap**, the tissue is brought from an area away from the open wound.

Local flap coverage of a wound is the next higher rung up the reconstructive ladder after a skin graft. Examples of wounds that require flap coverage include wounds with exposed bone, tendon, or other vital structure and large wounds over a flexion crease, for which a split-thickness skin graft or secondary closure would result in tight scarring.

Donor site: where the flap originates.

Recipient site: the open wound/soft tissue defect in need of coverage.

Pedicle: the blood supply of the flap (i.e., its arterial inflow and venous outflow). The pedicle varies from a wide bridge of tissue (skin, subcutaneous tissue, muscle, or some combination) to an isolated artery and vein.

Most local flaps can be classified as either (1) **skin flaps**, which are skin and subcutaneous tissue with or without the underlying fascia, or (2) **muscle flaps**, which are created from a muscle with or without the attached overlying skin.

Skin Flaps

A portion of skin and subcutaneous tissue and, when possible, the underlying fascia (the thin layer of connective tissue overlying muscle that has an excellent vascular supply) is moved to fill the defect. This movement of tissue results in a new defect at the donor site. Often the donor site can be closed primarily, but sometimes a skin graft is needed.

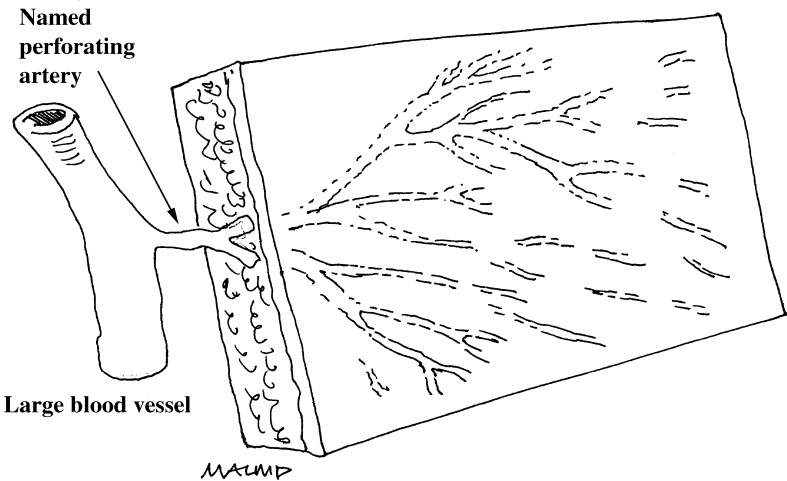
Classification

Skin flaps are classified as either **axial** or **random**. The classification is based on the blood supply.

Axial Flaps

The circulation of an axial flap is supplied by specific, identifiable blood vessels. Careful anatomic study has identified several donor sites with a single artery and vein responsible for circulation to a particular area of skin. Examples include the volar forearm skin supplied by the radial artery and skin on the back supplied by the circumflex scapular artery (a branch of the thoracodorsal artery).

Circulation based on specific vessels results in a highly reliable blood supply and a reliable flap. You can be confident that unless there is an injury to the vessels, the majority of the flap tissue should survive in its new position.



Axial flap. Note that the blood supply comes from an identifiable vessel. As a result, the pedicle can be quite thin, which makes transferring the flap to its new site an easier task.

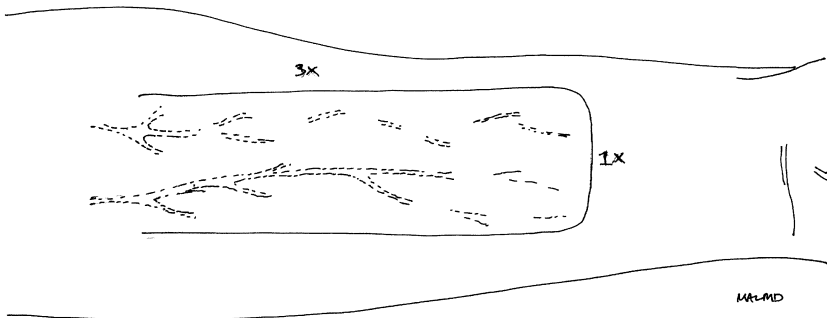
An axial flap can be completely detached from all surrounding tissue as long as it remains connected to its supplying blood vessels. These vessels serve as the pedicle. The thin pedicle allows axial flaps to be easily positioned to fill the wound defect (unlike the random flap [see below]).

The difficulty with an axial flap is locating the blood vessels. You must be very careful not to injure the vessels when creating the flap. The necessary technical expertise is beyond the realm of most providers without reconstructive surgical training. Thus, no specific axial skin flaps are discussed in this chapter.

Random Flaps

Circulation to a random flap is provided in a diffuse fashion through tiny vascular connections from the pedicle into the flap. The pedicle must be bulky to increase the number of vascular connections. The more vascular connections, the better the circulation to the flap. The better the circulation to the flap, the better its survival.

In general, a random flap does not have as reliable a blood supply as an axial flap. Nonetheless, the relative ease of creating random flaps makes them useful almost anywhere on the body. The circulation and thus the reliability of the flap can be increased by “delaying” the flap before final transfer.



Random skin flap. The blood supply comes diffusely from the remaining skin attachment, which serves as the pedicle. For optimal circulation and flap survival, the flap should be designed so that the length is no more than three times the width.

Delay Procedure

Before the flap is created, the tissue gets its blood supply via all of the surrounding skin and underlying tissue attachments. When the flap is created, the circulation to the flap comes only from the pedicle.

The purpose of the delay procedure is to enable the pedicle to assume its role as the main source of circulation before the flap is moved to its new position. This goal is obtained by making some of the incisions needed to create the flap but not separating the flap from the underlying tissues. The flap is not moved to its new position; instead, the skin edges are sutured together loosely.

The total blood supplied to the flap initially decreases when the incisions are made. This decrease promotes opening of new vascular channels between the pedicle and flap. Thus, more blood will flow into the flap through the pedicle than if the delay procedure had not been done.

Delaying the flap before final transfer allows more confidence in the viability of the flap. Wait about 7–10 days after the delay procedure before moving the flap to the recipient site.

Techniques for Creating Random Local Flaps

When creating a random local skin flap, you take advantage of the relatively loose, excess skin in the vicinity of the skin defect. Random flaps require less technical expertise than axial flaps. Because they can be quite useful for covering an open wound, several types of random flaps are discussed in detail below.

General Information

Random flap procedures often can be done under local anesthesia if the area (flap plus defect) is not too large (< 8–10 cm). For larger areas, general anesthesia probably will be required.

Be sure to clean the wound thoroughly before creating and placing the flap. Use a scrub brush or the flat part of a scalpel to scrape away the top layer of granulation tissue from the wound. Then wash with saline. The wound probably will bleed, but gentle pressure should control the bleeding.

Hint: Outline the flap before making any incisions. A water-based magic marker allows you to make corrections to your design before making any incisions. Incorrect marks can be removed by wiping with alcohol.

The part of the flap at highest risk for poor circulation is the tip of the flap (the tissue farthest from the pedicle). Unfortunately, the tip of the flap is usually the most important part of the flap because it is the part that provides coverage for the open wound.

To optimize circulation and reliability of a random flap, plastic surgeons heed the 3:1 rule. The flap should not be longer than 3 times its width. Delaying the flap is also useful.

Unfortunately, the thickness of the pedicle can make it difficult to move the flap to its new position. *Minimal tension should be applied to the flap when it is sutured into place.* Tension on the flap decreases circulation and can lead to tissue necrosis (death). You can tell that too much tension has been applied if portions of the flap look pale once it is in its new position.

If the donor site cannot be closed primarily without placing tension on the flap, avoid primary closure. A skin graft can be used to cover the donor site defect—or, if the defect is just a few cm, it can be allowed to heal secondarily.

For coverage of a wound > 7–8 cm, it is useful to place a drain under the flap to prevent collection of fluid, which will interfere with healing. The drain can be a suction drain, if available, or a passive drain (e.g., Penrose drain). A piece of sterile glove can substitute for a Penrose drain. The drain usually can be removed after 48 hours.

Rhomboid Flaps

Indications

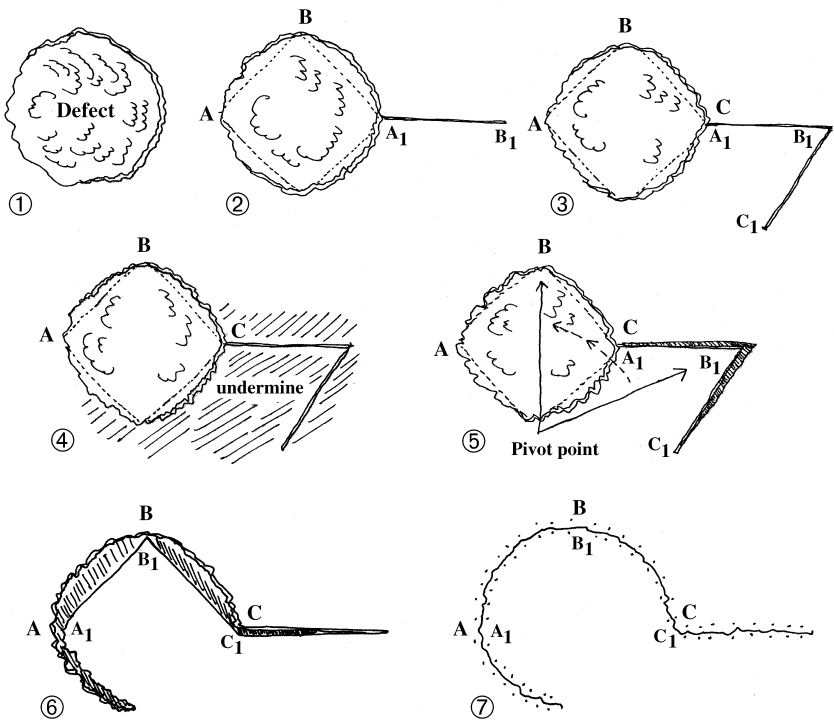
Rhomboid flaps are useful for wounds up to 4 or 5 cm in diameter on the face, trunk, or extremity. They are especially useful when there is not enough laxity in the surrounding tissues to create one of the other flaps discussed below.

Procedure

1. Measure the diameter of the defect.
2. Determine the site of greatest surrounding skin laxity (pinch the tissues to see where it is easiest to pull up on the skin). Draw a line from the wound edge into this tissue. This line, which represents the first incision, should be approximately 75% of the wound diameter.
3. Draw another line at a 60° angle to this extension, parallel to the edge of the defect. This line should be the same length as the line in step 2. These lines outline your flap.
4. Be careful not to make the pedicle of the flap too narrow.
5. Make the incisions along the lines placed in steps 2 and 3. Incise the skin and subcutaneous tissue of the flap down to, but not including, the underlying muscle.
6. Use a knife to lift the flap off the underlying muscle, trying to keep the fascia attached to the flap to enhance circulation. You should also separate the pedicle and some of the tissues around the wound

defect from the underlying muscle. This technique is called **undermining**. Undermining allows more mobility in the flap and surrounding tissues, which in turn facilitates wound and donor site closure.

7. The flap now should be ready to be moved into the wound, and the donor site should be closed primarily.
8. Loosely suture the flap in place, taking care to avoid tension on the pedicle. Place a few dermal sutures, and then do an interrupted skin closure. Be sure that the skin closure is not tight. It is better to have small gaps in the skin closure (which will heal) than to make a tight closure and lose part of the flap.



Rhomboid flap. 1: Open wound in need of coverage. 2: Draw a circle or rhomboid around the defect and, at the area of maximal skin laxity, a line 75% of the wound diameter. 3: Draw another line of the same length at a 60° angle to the first line, taking care not to narrow the base of the flap. 4, 5, and 6: Incise the lines. Undermine the area widely to allow transfer of the flap to the desired position and primary closure of the defect. 7: Final appearance of closed wound.

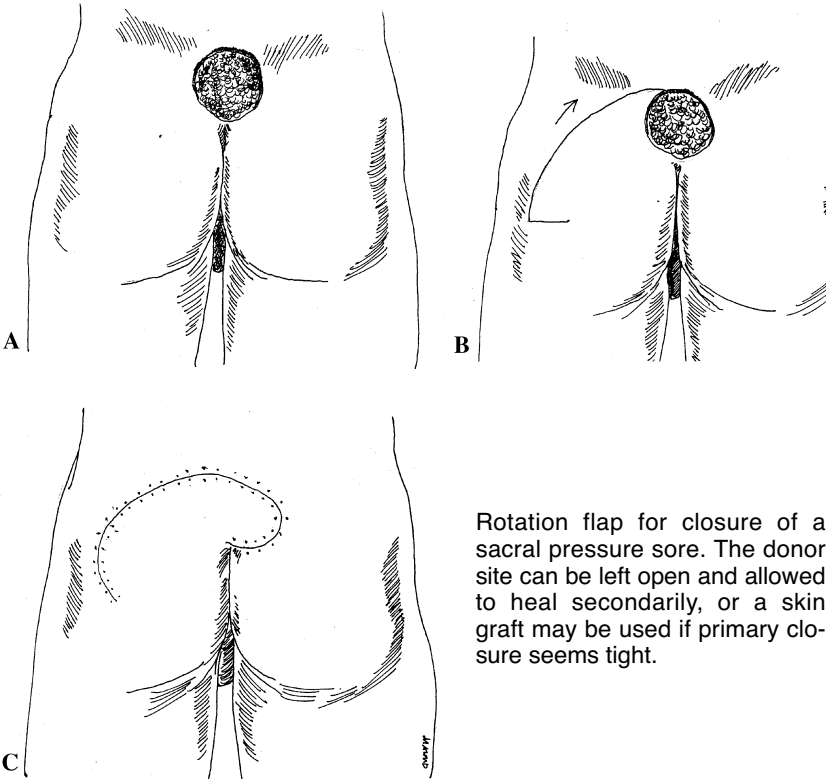
Rotation Flaps

Indication

Commonly used for coverage of sacral pressure sores. This type of flap can cover wounds of various sizes.

Procedure

1. Draw the flap before making any incisions so that you can make corrections.
2. Determine the site of greatest laxity in the surrounding tissues.
3. Make the flap larger than you think you need.
4. Extend the wound in a curved fashion until you think the flap can be moved into the defect. Be sure that the flap has a wide base (at least 8–10 cm).
5. Separate the flap from the underlying tissue attachments, and undermine the flap pedicle and surrounding skin edges.



Rotation flap for closure of a sacral pressure sore. The donor site can be left open and allowed to heal secondarily, or a skin graft may be used if primary closure seems tight.

6. If necessary, a small back cut can be made at the lateral edge of the base of the flap to help it turn onto the wound. Do not narrow the base by more than 1–2 cm.
7. Loosely suture the flap in place, avoiding tension on the pedicle. Place a few dermal sutures, and then do an interrupted skin closure. Be sure that the skin closure is not tight. It is better to have small gaps in the skin closure (which will heal) than do a tight closure and lose part of the flap.
8. Sometimes the donor site may need to be closed with a split-thickness skin graft or allowed to heal secondarily.

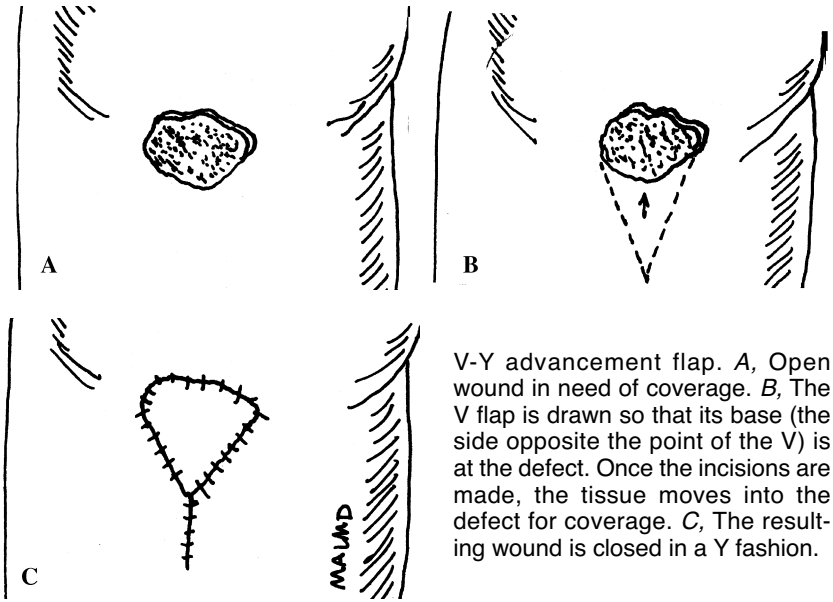
V-Y Advancement Flaps

Indications

V-Y advancement flaps are useful for covering ischial pressure sores and other wounds with very lax surrounding tissues. They may be used for both large (> 7–8 cm) and small wounds. V-Y advancement flaps are slightly different from those described above. The pedicle is not a bridge of surrounding skin and subcutaneous tissue; it is the deep tissue underlying the flap.

Procedure

1. Determine the site where the laxity of the surrounding skin is greatest.
2. Draw the flap before making any incisions so that you can make corrections.
3. Mark the V with the widest area at the edge of the wound, tapering gradually to a point.
4. Incise the skin edges through the subcutaneous tissue down to, but not into, the underlying muscle. The flap remains attached to the deep tissues.
5. The flap then should be advanced into the wound defect.
6. Close the defect primarily at the narrow point of the V. This step creates the Y limb.
7. Suture the flap loosely, under no tension. Place a few dermal sutures, and then close the skin with interrupted sutures. Do not make the skin closure too tight. It is better to have small gaps in the skin closure (which will heal) than do a tight closure and lose part of the flap.



V-Y advancement flap. A, Open wound in need of coverage. B, The V flap is drawn so that its base (the side opposite the point of the V) is at the defect. Once the incisions are made, the tissue moves into the defect for coverage. C, The resulting wound is closed in a Y fashion.

General Postoperative Care

Cleanse the suture lines with gentle soap and water and apply antibiotic ointment 1–2 times per day.

Remove the sutures within 7–10 days.

TROUBLE-SHOOTING

What to Do if the Flap Becomes Swollen and Bluish Within Hours after the Operation

A swollen, bluish flap indicates a problem with circulation into or out of the flap. Usually it is a venous (i.e., outflow) problem.

Make sure that the patient is positioned properly and that nothing is compressing or pulling on the pedicle. Loosen surrounding dressings and tape. Sometimes it is helpful to remove a few stitches to ensure that the flap is not under too much tension.

Be sure that no fluid has collected under the flap. Any collection of fluid requires drainage. Place a clamp between some of the sutures, and spread the skin edges. This technique helps to drain the fluid.

Ensure adequate pain control. Pain stimulates the sympathetic nervous system, which decreases blood flow through the pedicle.

What to Do If Part of the Flap Dies

A few days after the procedure, you may notice that a part of the flap has become purplish. A purple color indicates inadequate circulation to that part of the flap, and the tissue may eventually die.

If there is no evidence of infection, you may simply leave the flap alone. With time, this tissue will demarcate and die and then separate—or you may have to cut off the dead tissue. While this process is occurring, the underlying tissues will heal.

Muscle Flaps

Muscle flaps involve moving a local muscle to cover a defect. A muscle flap is often done to cover an exposed bone or fracture, usually in the calf. The muscle is freed from the surrounding tissues but left attached to its blood supply. A muscle flap is an axial flap.

Compared with skin flaps, muscle flaps bring in a robust, new circulation to the injured site and thus enhance wound healing. The use of muscle flaps to cover exposed fractures has markedly decreased the morbidity associated with open (compound) fractures.

For rural practitioners without access to a specialist, the muscle flaps of greatest utility involve primarily the lower extremity (see chapter 21, “Fractures of the Tibia and Fibula”).

Bibliography

1. Dhar SC, Taylor GI: The delay phenomenon: The story unfolds. *Plast Reconstr Surg* 104:2079–2091, 1999.
2. Taylor GI, Corlett RJ, Caddy CM, Zelt RG: An anatomic review of the delay phenomenon. II: Clinical applications. *Plast Reconstr Surg* 89:408–418, 1992.