



Chapter 12

SKIN GRAFTS

KEY FIGURES:

Skin anatomy with graft thickness	Mesher
Humby knife	Skin graft
Using the dermatome	Tying the dressing in place
Using the Humby knife	Defatting the FTSG

A skin graft involves taking a piece of skin from an uninjured area of the body (called the donor site) and using it to provide coverage for an open wound. When primary closure is impossible because of soft tissue loss and closure by secondary intention is contraindicated, a skin graft is the next rung on the reconstructive ladder. It is not a technically difficult procedure but does require some surgical skills. For a successful result, you need a thorough understanding of how skin grafts heal and how to perform the procedure.

Background information

Anatomy of Skin

The thickness of human skin is quite variable. The eyelids have the thinnest skin (0.5 mm), and the thickest skin is found on the soles of the feet (> 5.0 mm).

Epidermis

The epidermis is the top portion of the skin. The outer layers of the epidermis are formed by essentially dead, nonreplicating cells. The innermost layer contains the cells capable of replication, which are responsible for wound healing and skin pigmentation.

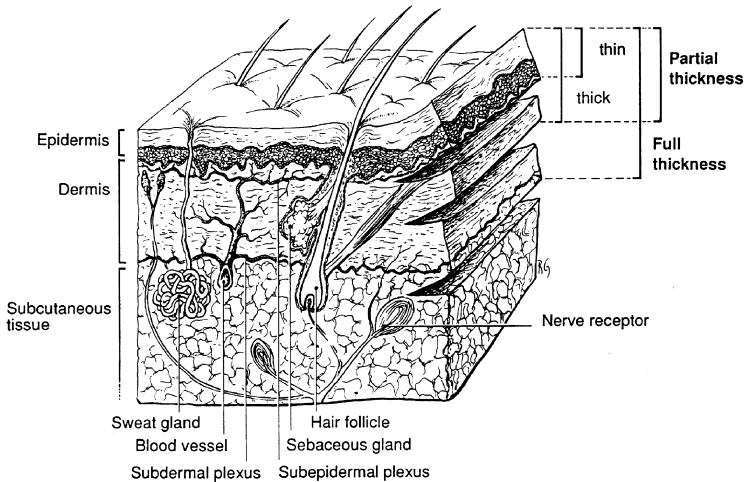
Dermis

Immediately below the epidermis is the dermis. It is made primarily of collagen and is much thicker than the epidermal layer. The dermal-epidermal

junction is irregular and has the appearance of ridges. This anatomic arrangement accounts for the skin's strength and prevents injury from normal shear forces. Nerve endings, hair follicles, and sweat glands are located in the dermis. *All skin grafts must include at least a portion of the dermal layer for survival.*

Subcutaneous Tissue

The subcutaneous fatty tissue below the dermis provides padding for the skin. The base of many hair follicles and sweat glands, as well as many important nerves for pressure sensation, reside in the subcutaneous tissue. Because of these important skin components, I include the subcutaneous tissue as a layer of the skin. However, it is not included in a skin graft. Fat attached to the graft interferes with transport of nutrients to the important upper skin layers. Therefore, no fat should be included in the skin graft.



Cross-section of human skin showing the epidermis and dermis (derived from two different germ layers). The relative thickness of skin grafts is shown. The thicker the graft, the more characteristics of normal skin it will provide. (From Cohen M (ed): *Mastery of Plastic and Reconstructive Surgery*. Boston, Little, Brown, 1994, with permission.)

How a Skin Graft Survives

When the skin graft is harvested from the donor site, it is completely separated from its blood supply. In its new position covering the open wound, the graft initially survives by diffusion of nutrients from the wound bed into the graft. Diffusion of nutrients keeps the skin graft

alive for, at most, 3–5 days. During this period, blood vessels begin to grow from the wound bed into the graft. By the time the graft is no longer able to survive by diffusion of nutrients alone, this vascular network has formed and becomes the primary mechanism for providing nutrients to the graft.

In the first several weeks after the procedure, the skin graft looks quite red and irregular compared with normal surrounding skin. Reassure the patient that the appearance will improve dramatically over the next several months, but the skin-grafted area will never look completely normal. It can take at least 1 year to see the final appearance of the graft. See chapter 15, “Scar Formation,” for more details

When is a Wound Ready for Grafting?

A wound will accept a skin graft when there is no overlying dead tissue and the wound is clean, beefy red (from granulation tissue), and without surrounding infection. Skin grafts heal well over muscle. Therefore, if muscle is exposed in the wound, skin can be grafted at any time, as long as the wound is otherwise clean.

Table 1. Compensating for Factors that Interfere with Graft Survival

Factor	Compensation
Dirty wound (e.g., surrounding infection, necrotic tissue over wound)	Debride the wound and treat it with wet-to-dry dressings until the wound looks clean. Use antibiotics to clear signs of surrounding infection. The skin graft can be done once the wound has improved in appearance and there are no signs of surrounding infection.
Fat in base of wound	Fat has a poor blood supply and may not be able to support the graft. Treat the wound with wet-to-dry dressings until granulation tissue* begins to appear. Then do the skin graft.
Shear forces between graft and base of wound	Movement of the graft over the wound interferes with vascular ingrowth. The graft must be kept well secured to the wound by the dressing. If the graft is on an extremity, consider using a splint for immobilization of the limb.
Blood or serum collection under graft	Fluid collection under the graft prevents the ingrowth of blood vessels necessary for graft survival. Fluid collection can be prevented by cutting holes in the graft and keeping the graft well secured to the wound. If the graft is on the leg, the patient should be kept on bedrest, with the leg elevated at all times for at least the first 4–5 days.

* Granulation tissue is the beefy red tissue that develops as a wound heals. It has an excellent blood supply but also contains bacteria in its crevices.

Contraindications to Wound Closure with a Skin Graft

A wound that has exposed tendon or bone can be successfully covered with a skin graft only if the thin layer of tissue connecting the tendon or

bone (paratenon or periosteum, respectively) is intact. These connective tissues contain the vascular structures necessary for skin graft survival. If the paratenon or periosteum is absent, the graft will not survive. Under these circumstances, some type of flap is needed for wound closure.

Split-thickness Skin Graft

A split-thickness skin graft (STSG) is composed of the top layers of skin (the epidermis and part of the dermis). The graft is placed over an open wound to provide coverage and promote healing. The STSG donor site is essentially a second-degree burn because only part of the dermis is included in the graft. The donor site will heal on its own because some dermal elements remain.

Indications

An STSG is indicated in most wounds that cannot be closed primarily and when closure by secondary intention is contraindicated. It is also indicated for a relatively large wound (> 5–6 cm in diameter) that would take many weeks to heal secondarily. A skin graft provides more stable coverage for large wounds than the scar that results from secondary closure. A large wound also heals more quickly with a skin graft than with dressing changes alone. The wound must be clean. All necrotic tissue must be removed before skin grafting, and there should be no signs of infection in the surrounding tissues.

Anesthesia of the Donor Site

Because of the relatively large size of the graft to be taken, the patient usually requires either general or spinal anesthesia for adequate pain control. However, if the required graft is no more than several centimeters in diameter, the donor site can be anesthetized by local infiltration of tissues with lidocaine or bupivacaine.

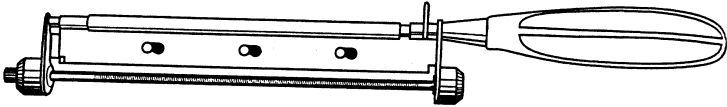
Preparation of the Donor Site

The most common donor site is the anterior or lateral aspect of the thigh. If the wound to be covered is on the back, try to take the graft from the lateral thigh, but the posterior thigh is also acceptable. Use of the posterior thigh as a donor site is a bit more painful and difficult for the patient to care for postoperatively.

Any betadine or other antibacterial solution used to prepare the donor site should be washed off with saline. Then the donor site should be dried. Apply a sterile lubricant (e.g., mineral oil, K-Y jelly) to the donor site and to the instrument you will be using to harvest the graft.

Procedure for Taking the Graft

A thin layer of skin (epidermis with some underlying dermis) is taken with a dermatome or a Humby knife (sometimes called a Watson knife). A dermatome is powered by air or electricity, but it is not available in all hospitals, especially in rural settings. Remember: you are *not* taking full-thickness skin; some dermis must be left at the donor site.



Skin-graft (Humby) knife. (From Padgett Instruments, Inc., with permission.)

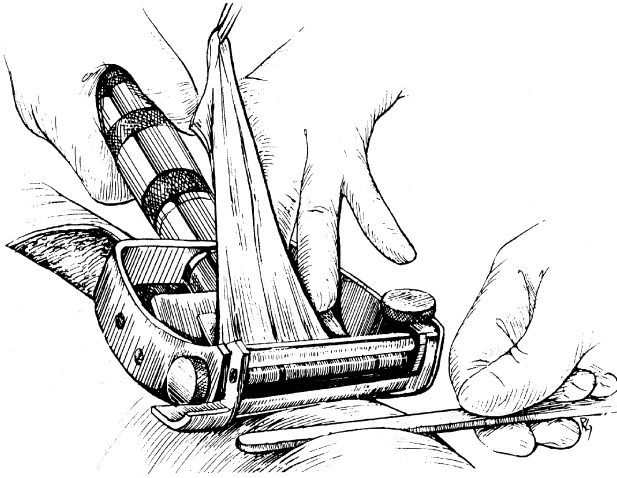
Both the Humby knife and dermatome have settings that can be adjusted to set the thickness of the graft. Place the settings at 0.011–0.015 inch (0.25–0.4 mm). Unfortunately, these settings are often unreliable. Another technique to ensure proper thickness of the graft is to adjust the opening of the blade so that you can snugly fit the beveled edge of a no. 10 blade into the opening.

Caution: Always check the knife settings just before you take the graft. This safety check prevents the accidental taking of too thick or too thin a graft.

An assistant should help to spread and flatten out the donor site by placing tension on the skin with gauze or tongue depressors.

If you have a dermatome:

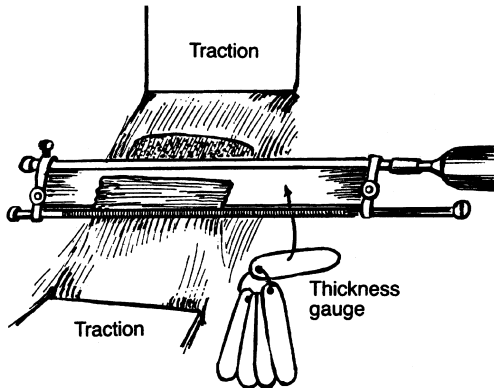
1. Turn on the power while the dermatome is in the air before it comes into contact with the skin.
2. Hold the dermatome at a 45° angle with the skin and hold it firmly against the skin.
3. Slowly move down the donor site until you have taken the properly sized graft.
4. At this point do *not* turn off the power. Remove the dermatome from the skin with the power on so that the graft is completely freed from the donor site.
5. The entire movement is evocative of landing an airplane and taking off again right away.



Harvesting a split-thickness skin graft with a power-driven dermatome. (From Cohen M (ed): *Mastery of Plastic and Reconstructive Surgery*. Boston, Little, Brown, 1994, with permission.)

If you have a Humby knife:

1. Hold it with the sharp edge at about a 45° angle with the skin.
2. With a back-and-forth motion run the knife over the tight skin.
3. When you have taken a large enough graft, continue the back-and-forth motion, and twist your wrist into supination to remove the knife from the skin. Another option is to stop the knife movement and then use a scalpel to cut the skin graft from the donor site at the

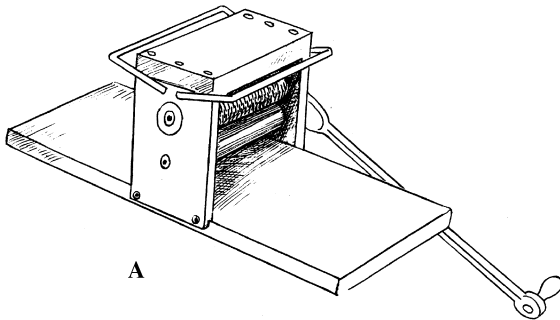


Harvesting a split-thickness graft with the Humby knife. (From McCarthy JG (ed): *Plastic Surgery*. Philadelphia, W.B. Saunders, 1990, with permission.)

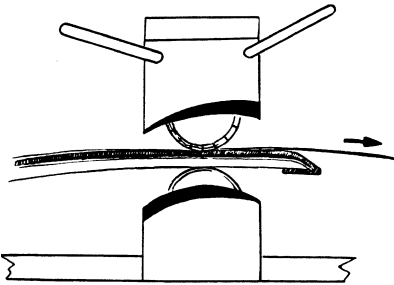
blade edge. You may need to open the knife fully to remove the skin from the instrument.

Preparation of the Skin Graft

It is best to cut multiple slices in the graft to prevent blood and serum from accumulating under the graft. The cuts also help to expand the graft, allowing you to take a graft that is slightly smaller than the open wound. Use the tip of a knife or a small scissors to create the cuts in the graft. Some operating rooms have special equipment, called meshers, for this purpose. The mesher is a hand-cranked instrument that creates pie-cuts in the skin.

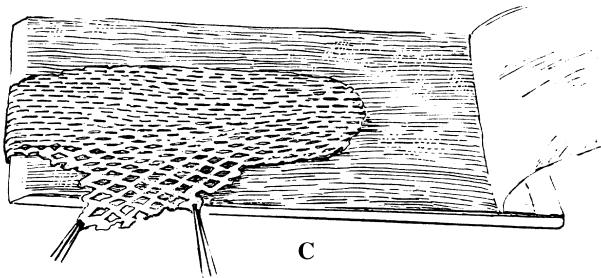


A



B

A, The mesher, a device used to make fine cuts in skin grafts. B, The skin graft is placed on the rough side of the carrier and passed through the mesher. C, The meshed graft can now be spread over a larger area. (From Chase CA: *Atlas of Hand Surgery*. Philadelphia, W.B. Saunders, 1973, with permission.)



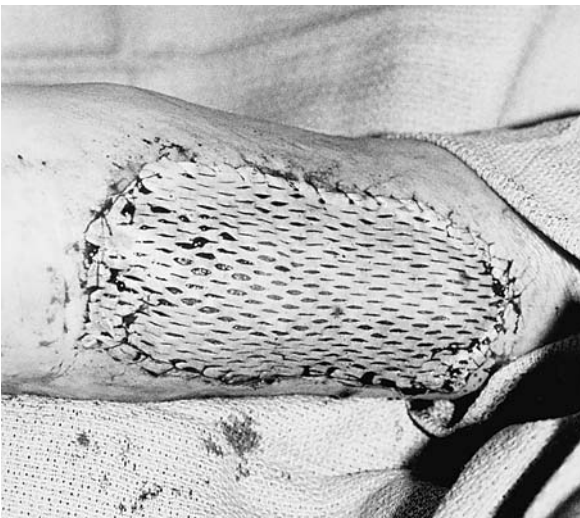C

How to Use the Mesher

1. Place the skin on a plastic carrier. Carriers are available in different sizes, but the best size to use is 1.5:1 (i.e., the graft is expanded 1.5 times).
2. Spread out the skin graft *on the rough side* of the carrier. If you put it on the smooth side, you will get spaghetti when you place the graft through the mesher. It does not matter which side of the skin faces upward on the carrier, but the dermis side is the more shiny side.
3. Pass the carrier with the skin graft through the mesher, taking care that the graft stays on the carrier and is not pulled into the blades of the mesher.

Placement of the Graft onto the Recipient Site

1. Be sure that the wound is clean. Remove any small areas that appear unhealthy.
2. To decrease the amount of contamination in the top layers of the healing wound, scrape the wound with the edge of a knife. Do not push the knife edge into the wound; instead, scrape it over the wound. Rinse the wound with saline.

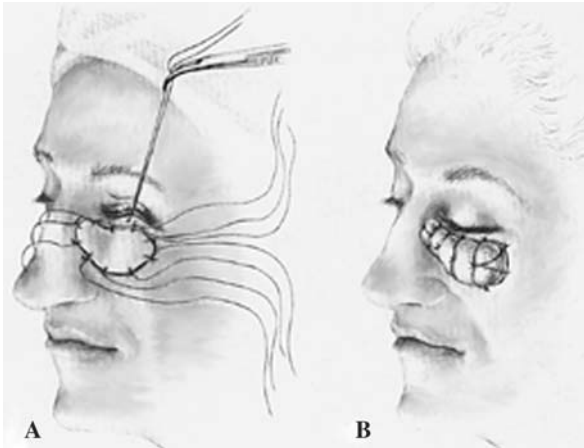


Wound covered with a split-thickness skin graft. The graft has been meshed 1.5:1.

3. Scraping the wound will make it bleed, but the bleeding is easily controlled by placing gauze over the wound and applying gentle pressure for a few minutes. Remember: hemostasis is important.
4. Place the skin graft over the wound with the **dermis side** (the shinier side) **down**, next to the raw surface of the wound.
5. Suture the graft in place with absorbable sutures. Leave a long tail on a few of these sutures so that they can be used to hold the dressing in place (see below).
6. Alternatively, the skin graft can be stapled in place, but the staples must be removed. Removal can be painful.

Application of Wound Dressing

1. A layer of nonstick material, such as antibiotic-impregnated gauze, should be placed directly over the graft. If you do not have this type of gauze, apply a layer of antibiotic ointment over the graft.
2. Moisten a sterile gauze with mineral oil (if available) or saline.
3. Fluff the gauze and place it over the nonstick layer; then cover the area with dry gauze.
4. Try to keep the dressing as secure as possible, either by wrapping with gauze or by tying the dressing in place.



Tying the dressing in place. In suturing the skin graft to the wound edges, leave the ends of each suture long (A). Then use the long ends to secure the dressing in place (B). This technique immobilizes the dressing and underlying graft. (From Edgerton M: *The Art of Surgical Technique*. Baltimore, Williams & Wilkins, 1988, with permission.)

Removal of Wound Dressing

- The dressing should be kept in place for 3–5 days. Check the dressing each day. If it develops an odor or has a lot of drainage, remove the dressing sooner.
- Be careful not to lift the graft from the wound with the dressing change. Wet the dressing with saline (mixed with a little hydrogen peroxide, if available) to prevent the dressing from sticking.

Aftercare

- Gently apply antibiotic ointment, or use a wet-to-wet saline dressing once or twice a day for the next few days. The area can be cleansed very gently with saline at each dressing change.
- After 10–14 days, once the wound looks like it is healing (i.e., the graft is pink and well-adherent to the wound), the dressings can be left off. A gentle moisturizer should be applied daily.
- The skin graft site should be kept out of the sun as much as possible. Sunscreens can be used once the graft has fully healed.
- Vigorously counsel the patient not to smoke during the healing period. Smoking probably will cause the skin graft to die.

Care of the Donor Site

- At the time of surgery, the donor site should be covered with a layer of antibiotic gauze. A thick layer of gauze should be placed on top.
- After 24 hours, remove the outer gauze dressing—not the antibiotic layer—and leave the entire area open to air. The layer of antibiotic gauze will dry out over the next 24–48 hours and gradually peel off as the underlying wound heals.
- An alternative treatment is to treat the donor site like a burn: apply antibiotic ointment twice a day until the wound has healed.
- Apply moisturizer regularly to the donor site once it has healed.
- The donor site also should be kept out of the sun. Sunscreens can be used once the wound has fully healed.

Full-thickness Skin Graft

A full thickness skin graft (FTSG) includes the epidermis and entire dermis but no subcutaneous fat. Because the entire thickness of skin is taken, the graft donor site must be closed primarily.

Indications

FTSGs are rarely done, because the wound must be *very* clean for the graft to survive. Most often they are used for a small wound, usually one created surgically (such as a wound on the face created by excision of a malignant skin lesion).

The other common use is for open wounds on the palmar surface of the hands and fingers. These areas may scar too tightly if the thinner STSG is used.

Preparation of the Donor Site

The best donor site is usually just above the inguinal crease on the lower abdomen. If the graft is needed to cover a facial wound, extra skin of a reasonable color match often can be taken from the supraclavicular area in the neck or from behind the ear.

An ellipse is drawn at the donor site. Make sure that it is large enough to cover the defect but not too large to close the donor site.

You can tell how large a graft you can take by seeing how much skin you can pinch or pull up at the donor site. At the inguinal area, you can flex the patient's hip to decrease tension on the closure. After a few days the patient will be able to extend the hip fully. This approach causes no long-term problems.

Anesthesia of the Donor Site

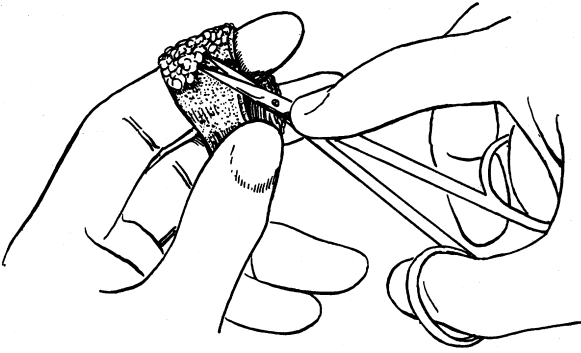
Because you are taking a relatively small graft, the FTSG can be harvested with a local anesthetic. Lidocaine and marcaine work equally well.

Procedure for Taking the Graft

1. The ellipse of skin is excised with the full layer of dermis. To facilitate the procedure, take the graft with some underlying fat attached.
2. You must remove the attached fat, which will interfere with graft survival.

How to Defat the Graft

1. The skin graft should be placed under tension. Place clamps on the ends of the graft, lay the graft over your hand, and let the clamps hang freely.
2. Use scissors to remove the fat on the dermis. Place the scissors flush with the skin, and cut away the fat. Do not worry if you take a little dermis or cut into small areas of the epidermis.



Defatting the undersurface of a full-thickness skin graft with a pair of scissors. (From McCarthy JG (ed): *Plastic Surgery*. Philadelphia, W.B. Saunders, 1990, with permission.)

Placement of the Graft onto the Recipient Site

1. The recipient site must be *very* clean.
2. If you are using the FTSG for a wound on the palmar surface of the hand, decrease the amount of contamination in the top layers of the healing wound by scraping the wound with the edge of a knife. Do not push the knife edge into the wound; simply scrape it over the wound and then rinse with saline.
3. Scraping makes the wound bleed, but the bleeding is easily controlled by placing gauze over the wound and applying gentle pressure for a few minutes. Remember: hemostasis is important.
4. A few small slits can be cut in the graft to prevent fluid from accumulating under the graft. In general, the graft is placed as an intact sheet. Do *not* mesh a FTSG.
5. The graft is placed over the wound, dermis side down, and sutured in place with absorbable sutures. Leave a long tail on a few of these sutures so that they can be used to hold the dressing in place.

Application of Wound Dressing

1. A layer of nonstick, antibiotic-impregnated gauze should be placed directly over the graft. Alternatively, place a thin layer of antibiotic ointment over the graft.
2. Moisten sterile gauze with mineral oil (if available) or saline.
3. Fluff the gauze and place it over the nonstick layer and cover with dry gauze.

4. Keep the dressing as secure as possible, either by wrapping with gauze or by tying the dressing in place.

Removal of Wound Dressing

The dressing should be kept in place for 3–5 days. Check the dressing each day. If the wound develops an odor or has a lot of drainage, remove the dressing sooner.

Be careful not to lift the graft off of the wound with dressing changes. If necessary, wet the dressing with saline (mixed with a little hydrogen peroxide if available) to prevent it from sticking.

Aftercare

Apply antibiotic ointment, or use a wet-to-wet saline dressing once or twice a day for the next few days.

Cleanse the area gently with saline at each dressing change.

The epidermis (very top layer) may become black and peel off. Do not be overly concerned. As long as the underlying dermis is attached and vascularized, the graft should heal.

After 7–10 days, once the graft looks like it is healing (i.e., it is pink and well-adherent), the dressings can be left off. A gentle moisturizer should be applied.

The skin graft site should be kept out of the sun as much as possible. A gentle sunscreen should be used.

Vigorously counsel the patient not to smoke during the healing period. Smoking probably will cause the skin graft to die.

Care of the Donor Site

The donor site should be closed primarily and covered with antibiotic ointment and dry gauze. The dressing can be removed after 24 hours.

Apply a small amount of antibiotic ointment and dry gauze for 2–3 days. Then the area can be left open.

Clean daily with gentle soap and water.

Remove the sutures after 7–10 days.

Bibliography

Reus WF, Mathes SJ: Wound closure. In Jurkeiwicz MJ, Krizek TJ, Mathes SJ, Ariyan S (eds): *Plastic Surgery: Principles and Practice*. St. Louis, Mosby, 1990, pp 20–22.