



Chapter 6

EVALUATION OF AN ACUTE WOUND

KEY FIGURE:

Irrigating a wound

This chapter explains the basics for evaluation and treatment of an acute wound. Proper evaluation helps to determine the appropriate next step—formal wound exploration or wound closure.

The **first step** is to control blood loss and evaluate the need for other emergency procedures (see chapter 5, “Evaluation of the Acutely Injured Patient”). The **second step** is to obtain a thorough history about the patient and the events surrounding the injury.

About the Patient

Tetanus Immunization Status

Tetanus is a devastating disease, causing muscle spasms that can lead to muscle rigidity and seizures. Without adequate treatment, one in three adults with tetanus will die. Although immunization has made tetanus uncommon, it always lurks in the background.

If the patient has not had a tetanus booster within 5 years, and the wound is tetanus-prone (see Table 2), a booster should be given. If the wound is not tetanus-prone but the patient has not had a tetanus booster within 10 years, a booster should be given. Patients who have never been immunized need human tetanus immunoglobulin as well as tetanus toxoid followed by completion of the full tetanus toxoid series.

Table 1. Doses of Antitetanus Drugs

Drug	Number of Doses	Dosage
Tetanus toxoid: booster	1	0.5 ml intramuscularly
Tetanus toxoid: full immunization regimen	3	0.5 ml intramuscularly; repeat in 4 wk and 6–12 mo after second injection
Human tetanus immunoglobulin	1	250 U, deep intramuscular injection

Note: Tetanus toxoid and immunoglobulin must be kept refrigerated at all times during transport from the factory. This requirement may be a problem in remote areas.

Pulsatile Bleeding at Time of Injury

Even if the patient is not bleeding at the time of your examination, the history of bright red, pulsatile bleeding at the time of injury implies an arterial injury. A thorough vascular exam is required, and formal surgical wound exploration is almost always indicated.

Medical Illnesses

Patients with diabetes are more prone to infections and wound-healing problems. Encourage diabetic patients to keep glucose levels well controlled to decrease the risk of complications. Malnourished patients and patients with human immunodeficiency infection (HIV) or a history of cancer also have wound-healing difficulties.

Smoking History

Tobacco smoking dramatically decreases circulation to the skin and slows down the wound-healing process. Medical professionals have a duty to tell all patients not to smoke. But the patient with an open wound should be specifically warned that smoking interferes with and perhaps prevents the healing process. Smoking also increases the risk for wound complications and poor cosmetic outcome.

Events Surrounding the Injury

Timing of the Injury

It is best to close an open wound within 6 hours of injury. Do not close a wound after 6 hours because the risk of infection becomes unacceptably high.

Wounds on the face are exceptions to this rule. The face has an excellent blood supply, which makes infection less likely. In addition, cosmetic concerns are important. It is therefore acceptable to close a wound on the face that is older than 6 hours (perhaps up to 24 hours or at most 48 hours), as long as you can clean it thoroughly.

Nature of the Injury

- A wound caused by a **clean knife** has a low risk of infection.
- A **dirty wound** carries a risk for tetanus. Wood may break off and leave pieces behind, increasing the risk for subsequent infection if the wound is not explored and washed out thoroughly.

- Any wound that may contain a **foreign body** should be explored and the foreign body removed.
- **Animal bites**, especially cat bites, often penetrate more deeply than you think. Bites on the hand should raise concern about involvement of an underlying joint. Oral bacteria may cause severe infections (see chapter 36, “Hand Infections”). Always consider the risk of rabies.
- **Human bites** also are associated with specific oral bacteria that may cause serious infections (see chapter 36, “Hand Infections”).
- **If any object penetrated the patient’s clothing or shoes** before piercing the skin, the chance for infection is increased because pieces of clothing may become embedded in the underlying tissues. If an object penetrated the patient’s tennis shoes, be concerned about a possible pseudomonal infection.
- **Crush injuries** may be associated with greater underlying damage than initially appreciated (see chapter 35, “Crush Injury”).
- **Gunshot wounds**: see chapter 37, “Gunshot Wounds.”
- **Thermal or electrical injury**: see chapter 20, “Burns.”

Concerns about Tetanus

Table 2. Risks for Tetanus

Wound Characteristics	Tetanus-prone	Not tetanus-prone
Time since injury	> 6 hr	< 6 hr
Depth of injury	> 1 cm	< 1 cm
Mechanism of injury	Crush, burn, gunshot, frostbite, puncture through clothing	Sharp cut (knife, clean glass)
Devitalized tissue	Present in	None present
Contamination (e.g., dirt, saliva, grass)	Yes	No

Concerns about Rabies

Be aware of the risk of rabies in the area where you work. Some countries—England, for example—have no cases of rabies because of tight animal controls. In most other countries, rabies is a real concern.

The primary animals associated with rabies infections include bats, raccoons, skunks, and foxes. Because different areas have a different risk for specific animals, know your area. Dogs and cats also can be infected; be sure to ask if the animal has been vaccinated against rabies. Livestock, rodents (e.g., rats, mice, squirrels), and rabbits are almost never associated with a risk of rabies.

If you have fears that the animal is rabid:

1. Thoroughly clean the wound with soap and water.
2. Administer human rabies immunoglobulin, 20 IU/kg total. If possible, administer one-half of this around the wound, and give the rest in the gluteal area intramuscularly (IM).
3. Administer one of the three types of rabies vaccines currently available: 1.0 ml IM in the deltoid area of adults and older children, outer thigh (*not* gluteal area) in younger children. Repeat on days 3, 7, 14, and 28.

Examination of the Wound

The wound must be cleansed thoroughly to allow full evaluation of the extent of injury.

Cleansing the Wound

Cleansing a wound *hurts*. Often you must start by anesthetizing the area. Infiltrate a local anesthetic around the wound, or administer a nerve block using a few milliliters of lidocaine (see chapter 3, “Local Anesthesia,” for a more thorough discussion).

For most simple wounds (i.e., no exposed bone or other vital organ), clean technique is adequate. You can use clean gloves and gauze instead of sterile ones.

The wound needs to be fully washed out to remove all foreign material and decrease bacterial content.

Irrigate the wound with several hundred milliliters of sterile saline until all dirt and foreign material are removed. Then irrigate a bit more (an additional 50–100 ml, depending on the size of the wound).

In patients with a puncture wound, you need to irrigate into the puncture, not just the external opening. You may need to cut into the puncture wound and enlarge it by 1–2 cm to appreciate the full depth of penetration and allow proper cleansing.

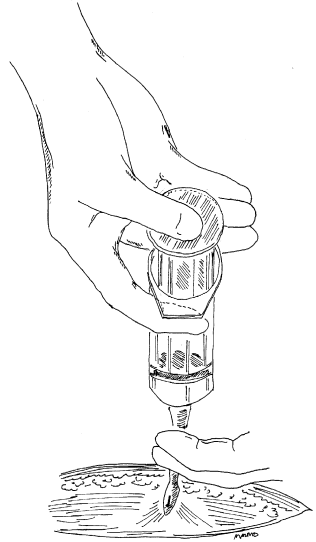
Wound Irrigation

Irrigation does *not* mean merely pouring some saline over the wound. You must apply the solution with some force to remove embedded debris and decrease the bacterial count.

The best method is to make an irrigating device out of a syringe (20–50 ml) with a 20-gauge angiocatheter (or whatever you use for intravenous access) or a blunt-tipped needle (a sharp needle can be used,

but be careful not to stick yourself). Draw the saline into the syringe and then squirt it out onto the wound. The 20-gauge catheter is best because it delivers the saline at an appropriate pressure to cleanse the wound and costs much less than larger-diameter catheters and needles.

Wound irrigation. Draw saline into a syringe. Place a 20-gauge, blunt-tipped catheter (preferably) or needle on the end of the syringe. Squirt the saline from the syringe onto the wound. Use some force. Repeat until the wound is clean. Usually a few hundred milliliters of irrigation are required.



Removal of Foreign Material, Devitalized Tissue, and Old Blood

Foreign material such as dirt, pieces of wood or grass, and parts of clothing must be removed because they are potential sources of infection.

An exception to this rule is a needle, bullet, or piece of glass deeply embedded in the tissues. In the absence of significant injury to surrounding tissue, these foreign materials usually can be left alone. They often are difficult to locate (even with x-ray guidance), and exploration may cause more local damage. Explain to the patient that the surrounding tissues usually wall off the foreign body. It may then gradually work its way to the skin surface, where it can be easily removed. Warn the patient that the foreign body may cause the area to become infected. If infection develops, localization and removal become much easier because you can follow the pus to the foreign body.

Obviously dead tissue in or around the wound should be removed. Remove any fat that appears to be almost completely detached from the wound, dark purple or black skin, or tissue embedded with debris or foreign material.

Old blood also must be removed. Blood is an excellent media for bacteria proliferation and infection.

If you are unable to remove the objectionable material completely, formal surgical exploration in the operating room with more adequate anesthesia (general and more local) is required.

Evaluation for Injury to Underlying Structures

Vascular Injury

If the injury is near a pulse point (e.g., in the groin near the femoral artery), check to be sure that a pulse is palpable in the nearby vessel—even if there is no active bleeding at the time of examination.

Check also for a palpable pulse in the vessel distal to the injury; for example, check pulses behind the knee or in the foot for a possible femoral artery injury.

Look for pulsatile bright red arterial bleeding or dark red venous oozing. Ensure that circulation to structures distal to the wound is adequate. Do so by checking capillary refill in the fingers or toes, as appropriate.

Testing Capillary Refill

A well-vascularized finger or toe generally has a pink hue under the nail. If it is blue or very pale, circulation may be impaired. Compare with the uninjured side to determine the patient's baseline status.

If you pinch the tip of the finger or toe, as appropriate, it should blanch (i.e., turn pale.)

Release the pressure. The color should return to normal within 2–3 seconds. A longer period may imply an arterial injury. A shorter period may imply a problem with venous circulation.

An arterial injury usually necessitates urgent surgical exploration in the operating room.

Nerve Injury

If injury occurs along the course of an important nerve, check for sensory and motor function.

A nerve injury in and of itself does not warrant urgent operation at the time of injury. A surgeon should explore the wound thoroughly and repair any injured nerves in the near future. The acute needs are thorough cleansing and loose closure to prevent infection and allow the wound to be fully explored at a later date.

Tendon Injury

If the injury occurs over the course of a tendon, evaluate the action of the affected tendon to ensure that it is appropriate.

A tendon injury in and of itself also does not warrant urgent operation at the time of injury. A surgeon should explore the wound thoroughly and repair any injured tendons in the near future. Again, the acute needs are thorough cleansing and loose closure to prevent infection and allow the wound to be fully explored at a later date.

Fracture or Joint Dislocation

In patients with an obvious bony deformity or a bone that is tender to palpation, get an x-ray to look for fracture or dislocation.

An open wound over a fracture or dislocation classifies it as an “open” or “compound” fracture or dislocation. This distinction is important because an open bone injury is associated with a higher risk of infection than a closed injury. Therefore, patients with an open injury must be placed on antibiotics immediately (a first-generation cephalosporin with or without an aminoglycoside, depending on the amount of bone and soft tissue contamination).

Unless the patient will be treated by an orthopedic surgeon within 24 hours, the wound should be cleansed thoroughly under general or regional anesthesia in the operating room. A finger fracture can be cleansed thoroughly with a digital block for local anesthesia. This procedure can be done in the emergency area or office.

If the wound can be closed, do so loosely. If soft tissue loss is apparent or if the skin is too tight to close primarily, the wound should be packed with sterile gauze moistened with saline or dilute Betadine. Reduce (align) the fracture or dislocation as best as possible, and immobilize the area. The patient should be evaluated by an orthopedic surgeon and possibly a reconstructive plastic surgeon if there is soft tissue loss.

What to Do Next

Active Bleeding

Apply point pressure over the wound. It is not enough to place gauze in the wound and wrap the area with an Ace wrap. You should place a wad of gauze over the injured area and use two fingers to apply point pressure. Push down firmly onto the wound. You may need to hold the pressure for 10–15 minutes before the bleeding will stop. If the bleeding is arterial, exploration is required.

If the patient has an exsanguinating (life-threatening) hemorrhage due to an extremity injury, place a tourniquet or blood pressure cuff proximal (closer to the heart) to the injury. The blood pressure cuff must be inflated to at least 50 mmHg above arterial pressure. *This technique hurts* and places the tissues at risk for ischemic injury. Therefore, the tourniquet should not be left in place for more than 15–20 minutes. If a tourniquet is needed, urgent operative exploration is required.

Foreign Body in the Depths of a Wound

Get an x-ray. Although many materials do not show up on x-rays, you may be able to see air or other indicators that give information about the depth of injury. The x-ray also can tell you whether an underlying joint was violated; air in the joint indicates injury.

Stab Wound over the Chest or Abdomen

You need to be concerned about penetration into the chest or abdominal (sometimes both) cavities. Such injuries should not be closed; they require further examination and evaluation to rule out internal injuries. Call a general surgeon.

* * *

Before further treatment, “paint” (i.e., wipe) the wound and the surrounding tissues with a small amount of Betadine or some other antibacterial agent.

The wound is now ready for one of the following definitive treatments.

Formal Wound Exploration

The patient is taken to the operating room and given general or regional anesthesia so that the wound can be fully cleaned and surgically examined under sterile conditions. Formal wound exploration is indicated in wounds with underlying vascular injuries, open fractures or dislocations, and wounds with extensive contamination, debris, or devitalized tissue.

Wound Closure

The method of closure often depends on the specific characteristics of the wound. Reconstructive plastic surgeons have organized the various techniques for wound closure into a hierarchy, sometimes called the “reconstructive ladder,” that ranges from the simplest to the most complex techniques. This hierarchy is set up so that if the first “step” does not work, it will not hinder attempts at the next step on the ladder. The “reconstructive ladder” gives you a logical way to think about how to close an open wound, regardless of its cause. Whether it

be an acute, traumatic wound or a wound that resulted from excising a tumor, the same principles apply. A brief overview follows; each step on the ladder is discussed more completely in subsequent chapters.

1. **Secondary closure** (leave the wound open). Sometimes it is best not to close a wound. Treat it with dressings, and allow it to heal on its own (healing by secondary intention). This technique is useful if soft tissue loss is apparent, if the wound cannot be closed without tension, or if you have concerns about infection. Certain wounds, however, require formal closure:

- Wounds with exposed vital structures, such as exposed bone, tendon, or nerve.
- Wounds in areas overlying creases; for example, the front of the elbow (antecubital fossa), back of the knee (popliteal fossa), or armpit. Subsequent scar contracture may severely limit function.

If formal closure is required, one of the following options should be used:

2. **Primary closure.** Skin edges around the wound are sutured together. The wound must be “clean” (i.e., no foreign material, no devitalized tissue, and no active bleeding). Tension in the closed wound should be minimal; therefore, there must be adequate skin to bring together without tension. As described earlier, primary closure is best done within 4–6 hours of injury. Except on the face or over a vital structure, delayed closure results in an unacceptably high infection risk, even with adequate cleansing.

3. **Skin grafting.** When the wound requires closure but cannot be closed primarily, a skin graft is often useful. Skin is taken from one area of the body as a free graft and placed over the wound. There are essentially two types of skin grafts: split thickness and full thickness. Skin grafts will not survive over exposed tendon or bone if the thin connective tissue covering is destroyed by the injury. A flap is required.

4. **Local flaps.** Like skin grafts, local flaps are used when the wound cannot be closed primarily. Flaps are needed for wounds with exposed underlying structures that require more than skin graft coverage. A local flap is created by moving nearby tissue—sometimes skin, sometimes muscle, sometimes both—to the wound for closure.

5. **Distant flaps.** When no useful local tissue is available to close the wound, tissue can be brought from a distant area. Sometimes the tissue is temporarily disconnected from the body; this technique is also called a free flap or a free tissue transfer. Tissue transfers also may be “walked” along the body in stages.

Bibliography

Gross A, et al: The effect of pulsating water jet lavage on experimental contaminated wounds. *J Oral Surg* 29:187, 1971.