



---

## Chapter 3

---

# LOCAL ANESTHESIA

### KEY FIGURES:

Digital block/anatomy	Ulnar nerve infiltration
Sensation to hand	Facial block:
Median nerve infiltration	skeleton

Full surgical evaluation of a wound and suture placement can be quite painful. You must anesthetize the injured area to perform these procedures properly. The administration of a local anesthetic allows you to evaluate and treat wounds in the emergency department or clinic. If you are unable to attain adequate pain control, the patient should be taken to the operating room for exploration under general anesthesia.

Local anesthetics work by reversibly blocking nerve conduction. They primarily block the sensation of sharp pain; they do not block pressure sensation. Therefore, in an area that has been adequately anesthetized, the patient will not feel the sharp needle stick during suture placement but may feel a vague sensation of pressure. This information should be shared with the patient.

The duration of effect depends on how long the agent stays in the immediate working area before being absorbed into the circulation or broken down by the surrounding tissues.

### ***Topical Agents***

Topical agents (agents applied on top of the surrounding skin and absorbed into the area to provide anesthesia without injections) are now available. However, they are quite expensive and can be used only on the surface, not deep within an open wound. They can be quite effective for performing simple excisions or starting intravenous lines. Although topical agents may become important in the future, because of their expense and limited usefulness, they are not discussed further in this chapter.

Application of cold works for only a few minutes but may allow enough time to place one or two stitches. Cold also may help by decreasing the pain of local anesthetic injection. It can be especially useful in children. Have the patient hold ice over the area for 5 minutes before injection. Another way to apply cold is to spray the area with ethyl chloride solution.

### ***Injectable Local Anesthetics***

The easiest and most reliable way to anesthetize a wound is to inject a local anesthetic. There are two techniques: (1) direct injection of the local anesthetic agent into the area around the wound and (2) injection of the anesthetic agent around a sensory nerve that supplies sensation to the injured area. Both methods are addressed below, but first the two most commonly used anesthetic agents are discussed. Neither needs to be refrigerated, which is important in the rural setting.

#### *Lidocaine (Lignocaine)*

Lidocaine is the most commonly used and least expensive agent. The usual total dose that can safely be given is 3–5 mg/kg body weight. Do not give more than this amount at one time. The anesthesia becomes effective after 5–10 minutes and lasts, on average, from 45 minutes to 1 hour.

#### *Bupivacaine (Marcaine)*

Bupivacaine is a longer-acting agent than lidocaine, but it is also more expensive. The usual total dose that can safely be administered at one time is 2.0–3.0 mg/kg. Bupivacaine takes a few minutes longer to become effective than lidocaine (10–15 vs. 5–10 minutes), but its effect can last 2–4 hours.

The longer duration of effect can be valuable. Some wounds take more than 1 hour to clean and suture. In addition, bupivacaine gives residual pain control after the procedure is completed. Hand injuries are especially prone to pain, making bupivacaine a good choice for treating hand and finger injuries.

If both lidocaine and bupivacaine are available, they can be mixed together in equal parts and administered with one syringe. This combination gives the advantages of the quicker onset of anesthesia from the lidocaine with the longer duration of action of the bupivacaine.

#### *Calculating the Amount to Administer*

To calculate the mg dose, multiply the ml of solution that you plan to give by the concentration of the solution (mg/ml). The following table

converts the commercially available anesthetic solutions to the mg/ml concentration of the anesthetic agent.

### Concentration of Agent in Commercially Available Anesthetic Solutions

Agent	Commercial Solution (%)	Concentration (mg/ml)
Lidocaine	0.5	5
	1.0	10
	2.0	20
Bupivacaine	0.25	2.5
	0.50	5.0

**Example:** You expect to inject 30 ml of 1.0% lidocaine to anesthetize a relatively large wound:

$$30 \text{ ml} \times 10 \text{ mg/ml} = 300 \text{ mg of lidocaine}$$

The patient is a 70-kg man. A 70-kg man can receive 3–5 mg/kg or 210–350 mg of lidocaine. Your 30-ml dose is on the high end of the “safe” range.

### *Additives*

It is sometimes useful to add additional drugs to the local anesthetic solutions to optimize their effect.

#### *Bicarbonate*

Both lidocaine and bupivacaine are acidic and therefore painful when injected. One way to lessen this pain is to add injectable sodium bicarbonate to the local anesthetic solution. Your patient will be grateful for this extra step. It is essential to use commercially prepared bicarbonate for injections. Do not try home-grown formulations. Be careful: adding too much bicarbonate to the anesthetic solution can lead to the formation of crystals. The proper mixtures are as follows:

- Lidocaine: add 1 ml of bicarbonate to each 9 ml of lidocaine before injection.
- Bupivacaine: add 1 ml of bicarbonate to each 19 ml of bupivacaine before injection.

#### *Epinephrine*

Epinephrine is a vasoconstrictor that shrinks blood vessels and thus reduces bleeding from the wound and surrounding skin edges. This makes wound examination and repair easier to perform. Epinephrine also decreases absorption of the anesthetic agent, which may allow safe injection of more than the usually recommended

amount of anesthetic agent. Epinephrine requires 5–7 minutes to take effect. The maximal dosages of lidocaine and bupivacaine with epinephrine are as follows:

- Lidocaine with epinephrine increases to 7 mg/kg, and its effect lasts 1½–2 hours.
- Bupivacaine with epinephrine: dosing essentially stays the same at 2.0–3.0 mg/kg, and its effect still lasts 2–4 hours.

Lidocaine and bupivacaine are available in solutions premixed with epinephrine, but you can add it to the anesthetic solution yourself. Be very careful, however, because the amount of epinephrine to add is very small:

1. Add 0.25 ml of 1:1000 epinephrine to 50 ml of local agent (50 ml is the usual-sized vial). This will give a 1:200,000 dilution—safe for most procedures.
2. Err on the side of adding a little less rather than a little more if you are drawing the epinephrine with a syringe larger than 1 ml.

### Contraindications to Adding Epinephrine

In certain circumstances the vasoconstricting effects of epinephrine can be detrimental and may lead to tissue loss. Examples include:

- Digital block (numbing the whole finger)
- On the tip of the nose
- On the penis
- Injury that results in a very ragged and irregular laceration. Epinephrine worsens the already compromised circulation of the skin edges.

### Indications for Adding Epinephrine

- Straight cut with healthy-looking skin edges
- On the face, oral mucosa, and scalp, which have excellent blood circulation

### Overview of Anesthetic Agents: Dosage and Duration of Action

Agents	Maximal dose (mg/kg)	Duration of Action
Lidocaine plain	3–5	45–60 min
Lidocaine with epinephrine*	5–7	1.5–2 hr
Marcaine plain	2.0–3.0	2–4 hr
Marcaine with epinephrine	2.0–3.0	2–4 hr

\* You can add the same amount of bicarbonate to solutions with epinephrine as you add to plain solutions without epinephrine (see above for proper amounts).

## ***Safety Hints***

**Caution about injections:** It is quite dangerous to insert the syringe needle in the wrong place and inject the solution into an artery by mistake. A good habit to develop when giving any type of injection is to *draw back on the syringe (i.e., pull back on the plunger) before injecting the solution*. If you draw back and get blood, reposition the needle and draw back again. This technique prevents an accidental intra-arterial injection, which can cause serious complications. If you draw back blood with the initial insertion, you have not created a major problem. Because you are using a small needle, you should not do significant damage to the blood vessel, but you may need to hold pressure over the area for a few minutes to decrease bruising.

**Caution about maximal safe dosage:** Be aware of how much you are injecting to avoid exceeding the safe doses. Average-sized wounds (up to 4–5 cm) usually present no problem, but it is easy to forget about dosage concerns when you are working on larger wounds. All anesthetic agents have systemic as well as local effects. The safe dosage is based on the total weight of the patient (thus the maximal doses are given as mg of agent/kg of patient body weight). Overdose can lead to seizures and even cardiovascular collapse or death due to the myocardial depressant and vasodilator effects of these agents.

## ***How to Administer the Local Anesthetic***

### ***Direct Infiltration Around the Wound***

In many cases, injecting the anesthetic agent around the wound is an easy and reliable way to anesthetize the area. It is best to use as small a needle as possible. The bigger the number, the smaller the needle: use a 25- or 27-gauge needle, and inject slowly. Injection of the anesthetic agent can be painful, and a slower injection rate causes less pain.

You can inject directly into the wound to get the anesthetic into the surrounding skin if the wound is reasonably clean. Alternatively, inject in the noninjured skin along the outside of the wound. Inject until you see the skin start to swell.

One technique is to push the needle into the tissues completely to the hub, and then slowly infiltrate the anesthetic as you bring the needle out of the tissues. Be sure to allow enough time for the agent to take effect before starting your procedure (at least 5 minutes).

### *Nerve Blocks*

In some areas of the body, discrete nerves that are responsible for sensation to the injured area are easy to locate. In these instances, local anesthesia can be infiltrated around (*not* into) the sensory nerve for pain control to the area around the wound. This approach is advantageous because the patient needs to undergo fewer injections than if you anesthetize the entire wound margins directly.

Nerve blocks are also a good choice when the wound is deep, because they often give a more complete block of the entire area, not just the skin. This approach is especially appropriate for larger wounds, because it usually requires less anesthetic agent than direct infiltration.

Whenever possible, use a relatively small needle (23- or 25-gauge) for the injection. *Always draw back on the syringe before injecting the anesthetic.* The nerves that you are blocking often are located near blood vessels.

**Caution:** You are probably injecting the anesthetic directly into the nerve if the patient complains of strong electric shocks or severe pain radiating along the distribution of the nerve. Stop the injection *immediately* and reposition the needle.

It usually takes a few minutes longer for the anesthetic to take effect than with direct wound injection. Often you must wait 10–15 minutes after giving a nerve block before proceeding with the procedure.

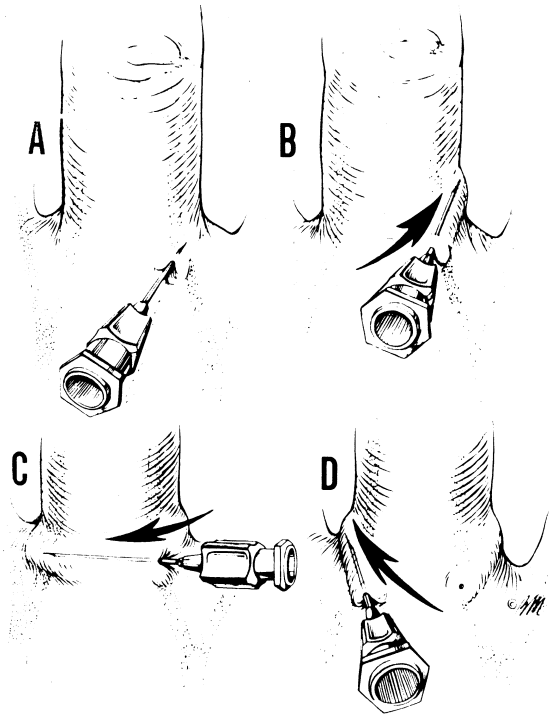
### ***Nerve Blocks for Hand Injuries***

Lidocaine, bupivacaine, or a combination of the two solutions can be used. Add bicarbonate if it is available. Epinephrine should *not* be used for anesthetizing the hand and fingers.

#### *Digital Block*

A digital block is the best way to evaluate and treat a wound on the finger. The digital nerves supply sensation to the volar and dorsal surfaces of the finger.

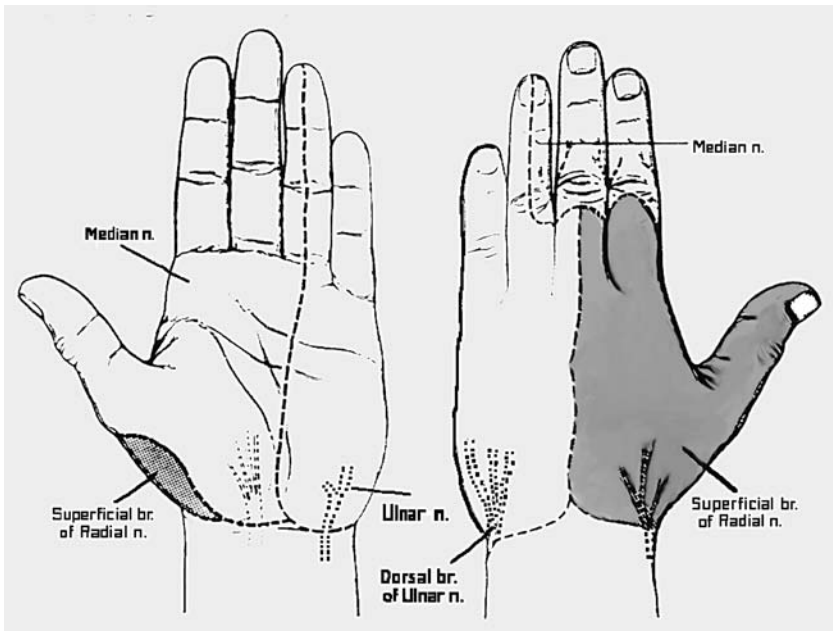
**Anatomy.** Each finger and the thumb have two digital nerves that travel with the digital vessels along the lateral and medial sides of the digit. Look at your own finger from the side, bend it at the two joints (distal interphalangeal [DIP] and proximal interphalangeal [PIP] joints). The line that connects the joint creases is a good estimate of where each digital nerve runs.



Digital nerve block, dorsal approach. Care must be taken to ensure that the anesthetic is not injected entirely circumferentially around the finger. (Illustration by Elizabeth Roselius. From Green DP, et al: *Operative Hand Surgery*, 4th ed. New York, Churchill Livingstone, 1999, with permission.)

### Procedure

1. The injection is done from the dorsal (not volar) surface near the metacarpophalangeal (MCP) knuckle.
2. Insert the needle into the web space, when present (the thumb and little finger are not bordered on both sides by web spaces).
3. Aim the needle toward the MCP joint of the affected finger, moving in a volar direction.
4. Be careful not to inject too superficially on the volar side, or your injection will miss the area around the nerve.
5. Inject 2–3 ml of solution into each side of the affected finger.
6. Infiltrate 1–2 ml along the dorsal skin of the digit, just distal to the MCP knuckle.



Pattern of sensory innervation of major peripheral nerves. (From Jurkiewicz MJ, et al (eds): *Plastic Surgery: Principles and Practice*. St. Louis, Mosby, 1990, with permission.)

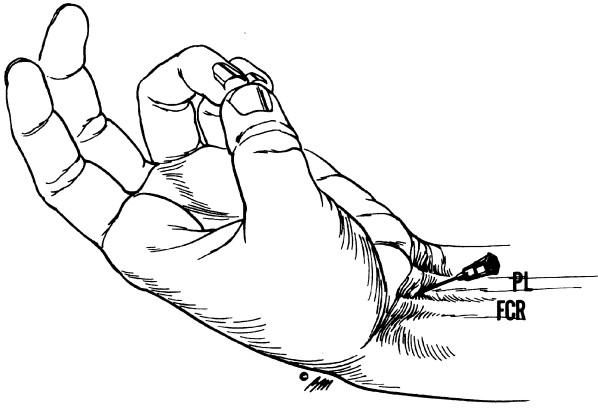
### *Wrist Block*

Three nerves supply sensation to the hand: the median nerve, ulnar nerve, and superficial branch of the radial nerve. If you infiltrate around all three nerves, you effectively anesthetize the entire hand. If an injury is within the distribution of any one or two nerves, simply infiltrate around the nerves that you need to anesthetize, based on the injury.

#### *Median Nerve*

The median nerve supplies sensation to the volar surface of the hand, from the lateral half of the ring finger to the thumb, and to the dorsal aspect of the fingers distal to the PIP joint, from the lateral half of the ring finger to the thumb.

**Anatomy.** At the wrist the median nerve lies between the palmaris longus (PL) and flexor carpi radialis (FCR) tendons. If the PL is absent (15% of the population), the landmark for injection is just medial to the FCR tendon.



Wrist block, median nerve. PL = palmaris longus, FCR = flexor carpi radialis. (Illustration by Elizabeth Roselius. From Green DP, et al (eds): *Operative Hand Surgery*, 4th ed. New York, Churchill Livingstone, 1999, with permission.)

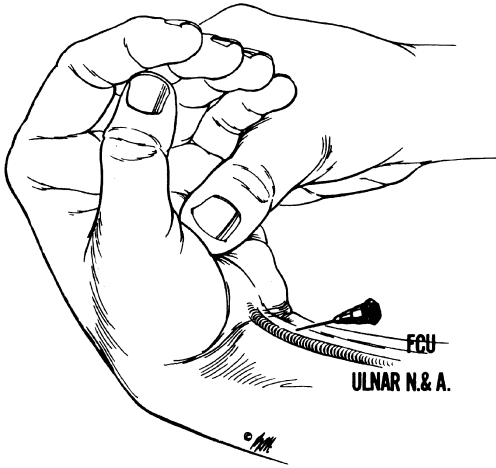
### Procedure

1. Have the patient flex the wrist. The FCR and PL (if present) become noticeable in the distal forearm; the FCR is the more lateral of the two tendons.
2. Insert the needle just proximal to the wrist crease and medial to the FCR tendon.
3. *Draw back on the syringe and slowly inject 3–5 ml of anesthetic in the tissues deep to the skin.*
4. If the patient describes minor tingling, the needle is in the proper position. If the patient describes electric shocks or severe pain, the needle may be in the nerve. Stop injecting the anesthetic, and back the needle out a few mm before continuing to inject the anesthetic solution. *Do not inject the anesthetic directly into the nerve.*

### *Ulnar Nerve*

The ulnar nerve supplies the remainder of the volar surface of the hand and the volar and dorsal surfaces of the ring and little fingers. The dorsal ulnar side of the hand is innervated by a branch of the ulnar nerve that comes off proximal to the wrist in the distal forearm.

**Anatomy.** At the wrist, the ulnar nerve lies with the ulnar artery lateral to the flexor carpi ulnaris (FCU) tendon. The artery is lateral to the nerve.



Wrist block, ulnar nerve. Note that the nerve lies between the artery and flexor carpi ulnaris (FCU) tendon. (Illustration by Elizabeth Roselius. From Green DP, et al (eds): *Operative Hand Surgery*, 4th ed. New York, Churchill Livingstone, 1999, with permission.)

### Procedure

1. Have the patient flex the wrist. The FCU is palpable along the medial edge of the distal forearm.
2. Insert the needle just proximal to the wrist crease and just lateral to the FCU tendon.
3. Draw back on the syringe before injecting the anesthetic to ensure that the needle is not in the ulnar artery. If blood is drawn back, remove the needle and hold pressure over the area for several minutes.
4. Slowly inject 1–2 ml of local anesthetic.
5. To block the nerve branch that supplies sensation to the dorsal aspect of the hand, inject 1 ml of local anesthetic subcutaneously in the tissues overlying the ulnar nerve.
6. Advance the needle onto the dorsum of the wrist, and inject another 3–4 ml. Go about halfway around the wrist on the dorsal surface.

### *Superficial Branch of the Radial Nerve*

The superficial branch of the radial nerve supplies sensation to the dorsum of the hand from the ring finger to the thumb; the dorsum of the thumb; and the dorsum of the index, middle, long, and ring fingers to the PIP joint.

**Anatomy.** The superficial branch of the radial nerve often has several branches traveling in the tissues of the dorsolateral surface of the distal forearm and wrist.

### Procedure

1. Feel for the radial artery pulse in the distal forearm, approximately 2 cm proximal to the wrist crease.
2. Insert the needle laterally to the point where you feel the pulse, and inject 1–2 ml of local anesthetic subcutaneously. *Draw back on the syringe before injection.*
3. Advance the needle into the tissues on the dorsum of the distal forearm.
4. Inject an additional 3–4 ml of solution halfway around the dorsal surface of the wrist.

## ***Nerve Blocks for Facial Injuries***

The nerves that supply sensation to the areas most commonly affected by facial trauma exit the skull along a line drawn perpendicular to the midpoint of the pupil. These nerves, designated as  $V_1$ ,  $V_2$ , and  $V_3$ , are branches of the fifth cranial (trigeminal) nerve.

Lidocaine and/or bupivacaine can be used for facial nerve blocks. Add bicarbonate if it is available. Epinephrine is often a useful addition to the anesthetic solution.

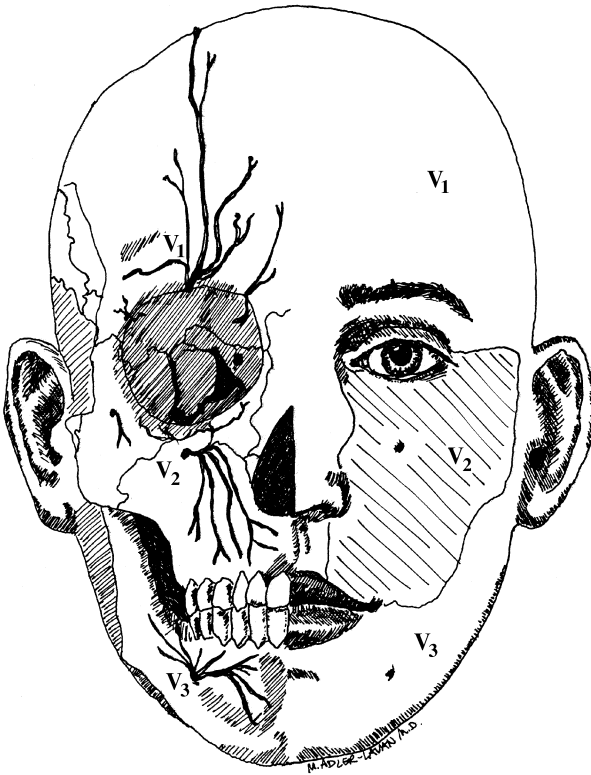
### *$V_1$ : Supraorbital Nerve Block*

The supraorbital nerves supply sensation to the upper eyelid and overlying forehead. A supraorbital nerve is located on each side of the face.

**Anatomy.** If you divide the supraorbital rim into thirds, the supraorbital nerve exits the skull at the point where the central and medial thirds meet.

### Procedure

1. Insert the needle into the eyebrow overlying the point where the nerve exits the skull.
2. Inject 1 ml of anesthetic solution into the superficial tissues.
3. Advance the needle downward to the bone. You will feel the needle hitting against a hard surface when it meets the bone.
4. Back the needle 1–2 mm away from the bone, and inject another 2–3 ml of local anesthetic.



Anatomy of the trigeminal nerve branches ( $V_1$ ,  $V_2$ , and  $V_3$ ). These nerves provide sensation to the face and are amenable to nerve blocks.

### *$V_1$ : Supratrochlear Nerve Block*

The supratrochlear nerve supplies sensation to the medial upper eyelid, upper nose, and medial forehead.

**Anatomy.** The supratrochlear nerve exits the skull along the medial aspect of the supraorbital rim just lateral to the area where the rim meets the nose.

#### **Procedure**

1. Insert the needle into the soft tissues overlying the point where you expect the nerve to exit the skull.
2. Inject 1 ml of anesthetic solution into the superficial tissues.
3. Advance the needle tip downward to the bone.
4. Back the needle 1–2 mm away from the bone, and inject another 1–2 ml of the solution.

**Caution:** For a forehead wound above the medial third of the eyebrow, both the supraorbital nerve and supratrochlear nerve probably need to be blocked on the side of the injury.

### *V<sub>2</sub>: Infraorbital Nerve Block*

The infraorbital nerves supply sensation to the upper lip, cheek, lateral aspect of the nose, and lower eyelid. There is one nerve on each side of the face.

**Anatomy.** The infraorbital nerve comes out of the skull about ½ cm below the orbital rim along the vertical line drawn perpendicular to the midpoint of the pupil.

#### **Procedure**

1. Insert the needle into the cheek skin at the point where the vertical line drawn perpendicular to the midpoint of the pupil meets a horizontal line drawn from the bottom of the nose.
2. Advance the needle tip 2–3 mm into the tissues.
3. Inject 1 ml of solution.
4. Advance the needle tip further, going in a slightly superior direction as you pass through the tissues until you hit the underlying bone. The tip ultimately should travel superiorly about 1 cm.
5. Back the needle out 1–2 mm, and inject another 2–3 ml of the anesthetic.

### *V<sub>3</sub>: Mental Nerve Block*

The mental nerves supply sensation to the lower lip and the skin immediately below it. There is one mental nerve on each side of the face.

**Anatomy.** The mental nerve exits from the mandible a few mm below and 5–10 mm lateral to the inferior aspect of the lower canine tooth root.

#### **Procedure.**

1. The mental nerve block is performed in the mouth.
2. Insert the needle into the mucosa a few mm below and 5–7 mm lateral to the root of the lower canine tooth.
3. Advance the needle tip until it hits the bone.
4. Inject 2–3 ml of solution.

### **Nerve Block Overview**

<b>Injury</b>	<b>Block</b>
Finger	Digital block
Palm of hand	Median and ulnar nerve block
Multiple cuts on both surfaces of hands	Wrist block
Left inner cheek/upper lip	Left intraorbital nerve block
Right lower lip	Right mental nerve block
Center of forehead	Supraorbital and supratrochlear block on both sides of face

### ***Sedation***

Sedation can be a useful adjunct to local anesthetic. A sedative decreases the patient's anxiety about the upcoming procedure and increases the patient's cooperation. This, in turn, makes the procedure easier and safer to perform.

In the setting of exploring or closing a wound, the purpose of sedative medications is not to put the patient to sleep, but to make him or her somewhat drowsy and less anxious.

**Caution:** Sedative medications can cause respiratory depression. Always start with small doses, and gradually give additional medication until the desired amount of sedation is obtained. Patients should be monitored closely (blood pressure, heart rate, and respiratory rate) during and for at least 1 hour after the procedure is completed.

There are many sedatives from which to choose. The following table gives information about two commonly used benzodiazepines.

### Useful Agents for Sedation

Agent	Route of Administration	Dose	Onset of Sedation (min)
Midazolam (Versed)	IV	<i>Adult:</i> 0.5–2 mg as initial dose; repeat cautiously with 0.5–1.0 mg after 3–4 min until desired effect is reached <i>Child (6 mo–13 yr):</i> 0.05–0.1 mg/kg/dose; repeat after 4–5 min until desired effect is reached to maximal total dose of 0.5 mg/kg <i>Child &gt; 13 yr:</i> follow adult dosing	2–3 (adult and child)
	IM	<i>Adult:</i> 2–5 mg <i>Child:</i> 0.1–0.5 mg/kg	<i>Adult:</i> 15–20 <i>Child:</i> 5
Diazepam (Valium)	IV	<i>Adult:</i> 5–10 mg <i>Child:</i> 0.04–0.2 mg/kg/dose	5–10 (adult and child)
	IM	<i>Adult:</i> same as IV dose <i>Child:</i> same as IV dose	30 (adult and child)

IV = intravenous, IM = intramuscular.

### ***For Information Only: Additional Blocks for Procedures on the Upper Extremity***

These procedures are technically more difficult and require special equipment. Although discussed for completeness, they are beyond the realm of a health care provider without expertise in delivering anesthesia.

#### *Bier Block*

In a Bier block, also called intravenous regional anesthesia, the affected hand or forearm is exsanguinated and an upper arm tourniquet is inflated. The venous circulation of the hand or forearm is then filled with lidocaine via a catheter placed in a hand vein before exsanguination. In this manner, the hand and forearm are anesthetized. The block lasts about 45–60 minutes.

**Warning:** The tourniquet must work perfectly. If the tourniquet does not hold its pressure, the injected lidocaine may become systemic and cause serious side effects (e.g., seizures, cardiac arrhythmias/arrest). In addition, for a very short procedure (< 15–20 minutes), the lidocaine in the veins will still be at too high a concentration for the tourniquet to be deflated. Usually, the tourniquet can be released safely after 25–30 minutes.

#### *Axillary Block*

An axillary block essentially anesthetizes the proximal portions of the

nerves that become the median, ulnar, and radial nerves in the forearm and hand. Technically these portions of the nerves are called the cords of the brachial plexus. The axillary block is commonly used to provide anesthesia for hand procedures.

Usually a mixture of lidocaine and bupivacaine is used for infiltration. An axillary block is useful for procedures that take up to 2½ hours.

The landmark for injection of the anesthetic is the axillary artery, which is easy to feel in the inner aspect of the upper arm. However, injecting in the vicinity of the axillary artery is not without risk; possible complications include injury to the artery or accidental intra-arterial injection. A nerve stimulator can be used to help to identify the nerve and thereby lessen these risks. Even so, an axillary block should be done only by health care providers with expertise in delivering anesthesia.

### ***Bibliography***

1. Cousins MJ, Bridenbaugh PO: Neural Blockade in Clinical Anesthesia and Management of Pain, 3rd ed. Philadelphia, Lippincott Williams & Wilkins, 1997.
2. Longnecker DE, Morgan GE, Tinker JH: Principles and Practices of Anesthesiology, 2nd ed. St. Louis, Mosby, 1997.